

# Small ventricular septal defects in adults

U. Neumayer, S. Stone and J. Somerville

*The Jane Somerville Grown-Up Congenital Heart Unit, Royal Brompton Hospital, London, U.K.*

**Aims** To establish the frequency of complications in adults with small ventricular septal defects, which have not undergone surgery.

**Methods and Results** One hundred and eighty-eight adults aged 17–72 (mean, 29.2) years with a small ventricular septal defect were studied. They were referred to a national cardiac centre (National Heart Hospital) and specialized grown-up congenital heart unit. One hundred and thirty-eight were examined in 1994–95. Fifty patients (26.6%) had additional cardiovascular lesions, most commonly a bicuspid aortic valve and/or coarctation. Spontaneous closure occurred in 19 (10%) between the age of 17 and 45 (mean, 27) years. Twenty-one (11.2%) had infective endocarditis. Aortic regurgitation developed in 37 (19.7%) patients; it was severe in nine. Atrial arrhythmias (supraventricular tachycardia or atrial fibrillation) occurred in 12 patients. In four patients, atrial fibrillation produced severe right-sided congestion with a left ventricular to right atrial shunt and haemodynamic features suggesting

'restrictive cardiomyopathy'. Four patients had ventricular arrhythmia. Disproportionate left ventricular enlargement on echocardiography and/or chest radiography was present in 26 (13.8%) without lesions to account for it.

**Conclusions** Eighty nine patients (47%) aged 17–44 (mean, 26.8) years had no complications through many years, while spontaneous closure occurred in 19 (10%) during adulthood. Forty-six (25%) had serious complications: infective endocarditis (11%), progressive aortic regurgitation (5%), age-related symptomatic arrhythmias (8.5%) and atrial fibrillation the commonest. Accepting that there may be a referral bias for those with complications, the course of a small ventricular septal defect is not necessarily benign during adult life.

(*Eur Heart J* 1998; 19: 1573–1583)

**Key words:** Small ventricular septal defects, adult congenital, complications.

## Introduction

The small ventricular septal defect has been considered benign, not needing any treatment through life other than prophylaxis for a low risk of endocarditis. However, there have been suggestions that this is not always true<sup>1–3</sup>. In order to establish the frequency of complications in adulthood, a cohort of adult patients (over age 16 years) with small ventricular septal defects from a national cardiac centre, with an established unit dedicated to the care of grown-up congenital heart disease, has been studied.

## Material and methods

The Grown-Up Congenital Heart (GUCH) Unit database at the Royal Brompton Hospital and Harefield NHS Trust in London was searched for patients with ventricular septal defect aged 16 years and over.

Revision submitted 12 March 1998, and accepted 24 March 1998.

*Correspondence:* Dr Jane Somerville, Royal Brompton Hospital and Harefield NHS Trust, Sydney Street, London SW3 6NP, U.K.

Included in the study were patients who had not been operated on in childhood, as the defect had been accepted as 'small' and met the criteria summarised in Table 1<sup>2</sup>. Exclusion criteria are listed in Table 2.

Initially, 200 patients meeting the above criteria were found by searching the database. One patient had already died and 61 patients last seen between 1988 and 1993 could not be traced (33) or refused to attend for a follow-up visit (28). Twelve patients who had last been seen before the age of 16 years and were lost to follow-up (11) or did not attend for a follow up visit (1) were excluded. The study was therefore made on 188 patients. Thirty-five patients were fully evaluated in 1994, 103 attended in 1995–96. Each patient had a clinical examination, electrocardiogram, chest radiography and transthoracic echocardiogram; in 19 cases this was performed locally and transmitted to us. The follow-up period for this study was considered from the patient's 16th birthday to the year he/she was last seen. The date of surgery was taken as the end-point of follow-up, in patients who had surgical closure of their defects after age 16 years. Patients whose defects closed spontaneously after age 16 years continued to be reviewed.

**Table 1** Criteria for 'small' ventricular septal defects included in the study

- Qp:Qs=2:1 or less in absence of pulmonary hypertension or pulmonary stenosis
- Mean pulmonary artery pressure <25 mmHg at catheterization after the first year of life\*
- Max. diameter <1 cm on echo (adult) with a gradient between the left and right ventricle suggesting pulmonary artery pressure <40 systolic.
- In the absence of cardiac catheter and no or insufficient echocardiographic data:
  - no symptoms in childhood
  - pansystolic murmur at lower left sternal edge
  - normal heart size on chest radiography

\*We included a few patients with moderate pulmonary hypertension (mean pulmonary artery pressure between 26 and 40 mmHg) which we considered secondary to left ventricular dysfunction, when a small shunt had been documented earlier in life or patients fulfilled echocardiographic and clinical criteria as stated above.

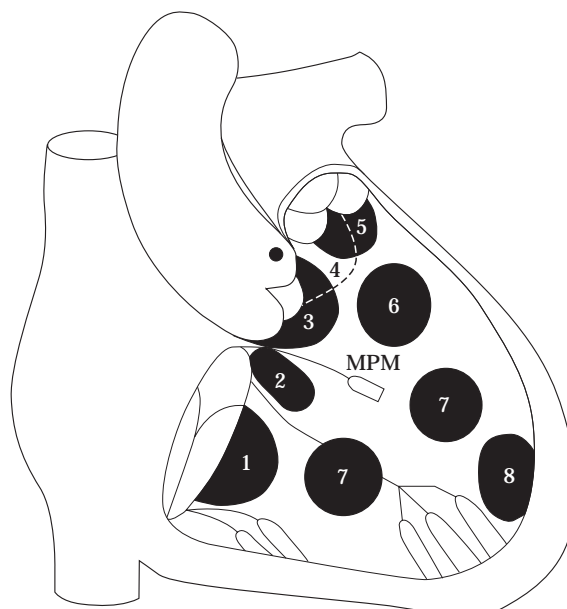
**Table 2** Patients who were excluded from the study

- Intracardiac surgery before age 16 years
- Double inlet or double outlet right or left ventricle
- Classic or corrected transposition
- Atresia of any valve
- Fallot's tetralogy
- Truncus arteriosus, hemitruncus
- Absent pulmonary valve
- Atrioventricular defects
- Patients in whom the defect had closed spontaneously before age 16 years
- Patients whose notes had been lost or destroyed

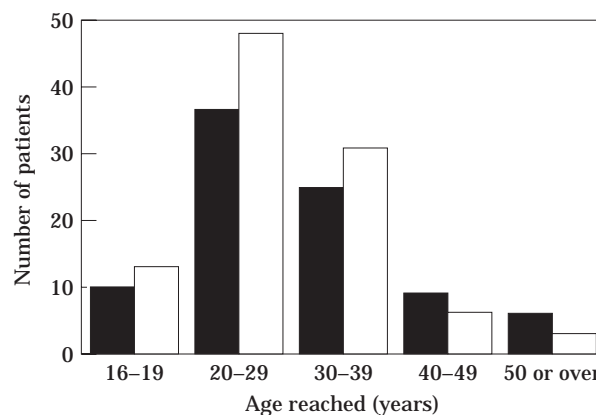
Clinical notes, electrocardiograms and, where possible, catheter data (91 patients) and echocardiograms (174 patients) were reviewed or obtained. Electrocardiographic and echocardiographic parameters, heart size on chest radiography, symptoms, ability index, spontaneous closure, any complications and need for surgical closure were evaluated.

### Classification of ventricular septal defects

The ventricular septal defects were classified by echocardiography as subvalvular or muscular.<sup>[4]</sup> Subvalvular defects are directly related to atrioventricular or semilunar valves or both, with bordering valvular tissue and no interposed muscle; they are further distinguished as subtricuspid, submitral (inlet), subaortic, subarterial doubly committed and subpulmonary defects, in relation to the contiguous valve. Muscular defects are completely bordered by muscle and may be apical, central and outlet (Fig. 1). Subtricuspid defects are frequently associated with a shunt from the left ventricle into the right atrium through a 'cleft', tethering or shrinkage of the septal cusp of the tricuspid valve<sup>[5]</sup>.



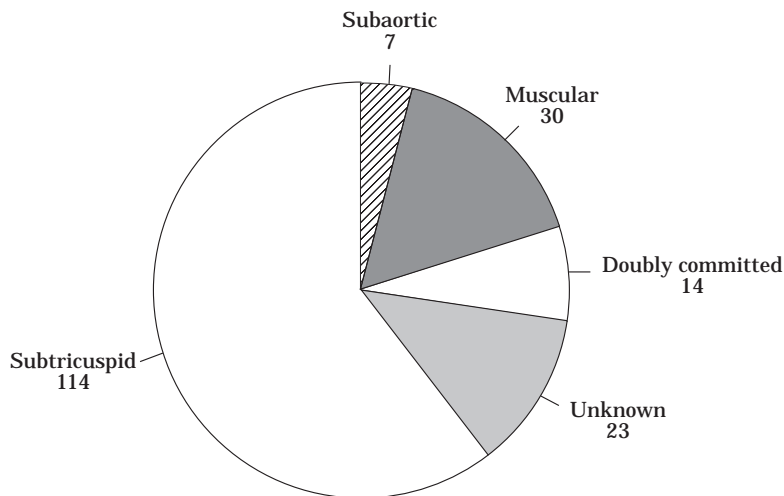
**Figure 1** Classification of the site of ventricular septal defects as viewed from the right ventricle 1–5, subvalvular: (1) inlet, (2) subtricuspid, (3) subaortic, (4) subarterial doubly committed, (5) subpulmonary. 6–8, muscular: (6) outlet, (7) central, (8) apical. MPM=medial papillary muscle.



**Figure 2** The gender (■=male; □=female) and age reached at last follow-up of patients with a small ventricular septal defect.

### Study population

One hundred and eighty-eight patients were included in the study, 101 women and 87 men. The patients' age when last seen was 17–72 years (mean 29.2) with period of follow-up between 1 and 56 years (mean 13.2; Fig. 2). Twelve (6%) patients were first referred to our centre because of complications; aortic regurgitation (2), bacterial endocarditis (5), heart failure (3) and 'palpitation' (2). The majority (168) were referred because they were known to have a murmur in childhood and followed on into adulthood by the GUCH Unit or referred from other paediatric cardiac units or referred in adolescence or adult life for diagnosis.



**Figure 3** The anatomical site of the ventricular septal defect in 188 patients using the classification in Fig. 1.

**Table 3** Small ventricular septal defect; associated congenital cardiovascular lesions

	Number of patients	Site of ventricular septal defect				
		Subtricuspid	Subaortic	Doubly committed	Muscular	Unknown
Coarctation of the aorta	15	9	0	1	5	0
Bicuspid aortic valve	16	5	0	2	6	3
Pulmonary stenosis	6	3	0	2	0	1
Infundibular stenosis	6	2	2	2	0	0
Wolf-Parkinson-White Syndrome	3	2	0	0	1	0
Persistent ductus arteriosus	3	3	0	0	0	0
Atrial septal defect	1	1	0	0	0	0
Right aortic arch	3	1	0	1	0	1
Accessory left superior vena cava	4	2	0	0	1	1
Mitral valve prolapse	6	5	0	0	0	1
Abnormal coronary arteries*	1	1	0	0	0	0
Hypertrophic cardiomyopathy	1	1	0	0	0	0
Total	65 (in 50 patients)	35	2	8	13	7

\*Left anterior descending arising from right coronary artery and passing behind the aortic root, arterial circumflex arising from the right sinus — intramural course.

Fixed subaortic stenosis is not included because it is considered to be 'acquired' but is discussed separately (see text).

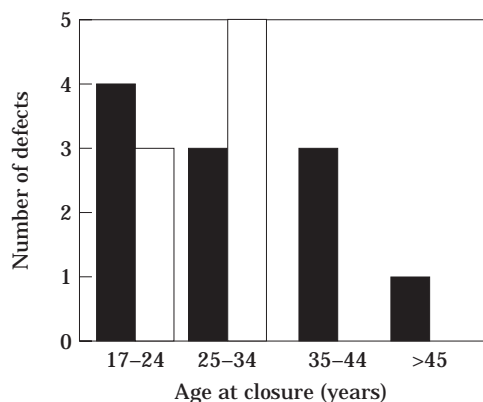
The localization of the defects is summarized (Fig. 3). The site of the defect was unknown in 23 patients because they had no echocardiogram and would not return (14 patients) or because the defect could not be seen on the current echocardiogram (one patient) or had closed spontaneously when there had been previous oxymetric and left ventricular angiographic documentation and recording of a pansystolic murmur (eight patients). There was difficulty in classifying the defects, described by the surgeon as 'subaortic' in seven patients who had surgery without prior echocardiographic study available for review. As the term 'subaortic' is currently used for any subvalvular defects, and in our experience subaortic defects are usually large<sup>[4]</sup>, we suspect that these patients had, in reality, subtricuspid or small doubly committed defects.

The diagnosis of small ventricular septal defect was made or confirmed by cardiac catheterization in 91 patients (data available in 84), by echocardiography in 169 patients and purely clinical in seven. Fifty patients (26.6%) had associated congenital lesions in the cardiovascular system with more than one associated lesion in 15 (8%) (Table 3). Bicuspid aortic valve and/or coarctation of the aorta were the most common occurring in 24 (12.8%).

## Results

### Survival

Three patients are known to have died during the follow-up period. One, a 67-year-old male with mild to



**Figure 4** The site of the ventricular septal defect (■ = subtricuspid; □ = unknown) and age when spontaneous closure was noted in 19 patients (10%).

moderate acquired aortic regurgitation, died suddenly following prostatic surgery (patient 100, see later) and one aged 26 years, a normally asymptomatic male, died suddenly (see arrhythmia section). The third death occurred in a 42-year-old male with added 'myopathy', atrial fibrillation and chronic right heart failure who died from Gram-negative septicaemia. Twenty-two of the patients included in the study could not be traced to the end of the follow-up period.

#### *Spontaneous closure of ventricular septal defect*

In 19 patients (10%) the defect closed spontaneously between age 17 and 45 years (Figure 4). The site was unknown (8) or subtricuspid (11). In the latter, redundant tricuspid tissue could often be seen on echocardiogram and acquired mild tricuspid regurgitation was commonly observed; two retained residual mitral regurgitation and an enlarged left ventricle. An 'aneurysm' of the membranous septum was seen on the echocardiogram in 12 patients with small, incompletely closed, subtricuspid defect. Two patients developed fixed subaortic stenosis taking the form of a fibrous ridge (gradient of 20–30 mmHg) after the ventricular septal defect

had closed; one developed complete right bundle branch block by the time the subaortic ridge was noted.

#### *Surgical closure*

In 20 (10.6%) patients, surgical closure of the defect was performed in adult life, age 17–44 (mean 25, median 22) years. Indications are listed in Table 4. All defects were subvalvular.

#### *Symptoms*

One hundred and thirty-six patients (72%) were free from cardiac symptoms during the follow-up period. Symptoms attributable to other lesions occurred in six (Table 5). Reversible symptoms related to the defect were due to endocarditis (21 patients) or aortic regurgitation cured by surgery (5); three of the four with right heart failure were improved by surgical closure. Persistent symptoms were 'palpitation', with or without some dyspnoea (16) and chronic 'right heart failure' (4). Persistent serious symptoms were age-related, increasing after age 40 years. Endocarditis occurred in all decades and symptomatic aortic regurgitation was more common in younger patients (Fig. 5).

#### *Specific complications*

##### *Infective endocarditis*

Twenty-one patients (11.2%), all with subvalvular defects, had bacterial endocarditis, five had two attacks; most frequently affected were the aortic and tricuspid valves, contiguous to the defect. There was often a considerable delay in diagnosis as fever and malaise had been treated with non-specific antibiotics over several weeks to months. In seven patients operation was performed to control infection; surgery involved not only closure of the defect but also aortic valve replacement (3) and tricuspid valve repair (3). In one patient in whom the diagnosis was delayed for 5 months (despite a positive blood culture after a miscarriage and dilatation

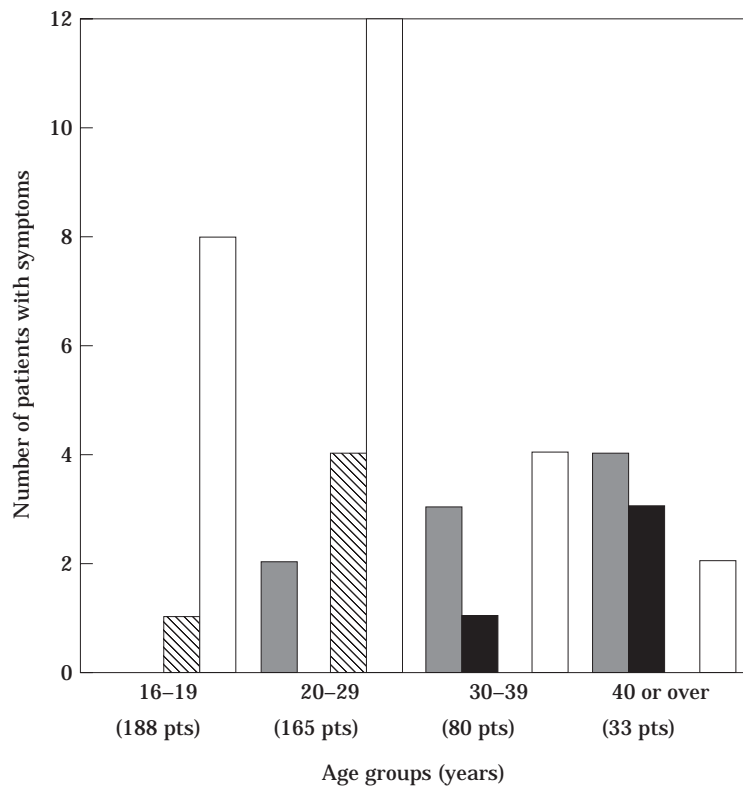
**Table 4** Indications for surgical closure

	Number of patients	Site of ventricular septal defect		
		Subtricuspid	Subaortic	Doubly committed
Bacterial endocarditis	10	5	4	1
Aortic regurgitation	5	1	2	2
Subaortic stenosis	1	0	1	0
Valvar aortic stenosis	1	0	0	1
?Cardiomyopathy	1	1	0	0
Right ventricular outflow tract obstruction	2	1	0	1
Total	20	8	7	5

**Table 5** Patients with symptoms due to associated cardiac lesions

Patient number	Site of ventricular septal defect	Associated cardiac lesion(s)	Problems	Symptoms	Age at onset of symptoms (years)
18	Muscular central	Bicuspid aortic valve	Severe aortic regurgitation	Dyspnoea, reversed after aortic valve replacement (age 20 years)	19
53	Subtricuspid	Coarctation+atrial septal defect, repaired age 45 years	Atrial fibrillation, systemic hypertension	Palpitations, dyspnoea	45
102	Subtricuspid	Hypertrophic cardiomyopathy (end-stage)	Atrial fibrillation, congestive failure	Palpitations, dyspnoea, oedema	53
116	Subtricuspid	Abnormal coronary arteries*	Ischaemic cardiomyopathy	Angina, dyspnoea	37
178	Subtricuspid	Subaortic stenosis peak gradient=105 mmHg		Effort dyspnoea, improved after resection (age 17 years)	17
188	Doubly committed	Infundibular stenosis peak gradient=70 mmHg		Effort dyspnoea	40

\*Left anterior descending arising from right coronary artery and passing behind the aortic root, arterial circumflex arising from the right sinus — intramural course.



**Figure 5** The age/decade of patients with a small ventricular septal defect when symptoms noted. In this figure, patients with a bicuspid aortic valve and those with conditions predisposing to atrial fibrillation (end-stage hypertrophic cardiomyopathy, acquired coronary artery disease and closed atrial septal defect) are not included. ■ = arrhythmia with failure; ▣ = arrhythmia (without failure); ▤ = serious aortic regurgitation; □ = bacterial endocarditis.

and curettage) an abscess of the aortic root extending to the anterior mitral leaflet was present, requiring emergency surgery; the aortic valve and root were replaced with an aortic homograft, the defect was closed

and vegetations removed from tricuspid, mitral and pulmonary valves. A further three patients had elective closure of the ventricular septal defect after the first or second episode of endocarditis. No deaths occurred in

**Table 6** Summary of anatomical and pathological features in 37 patients with acquired aortic regurgitation

	Number of patients	Site of ventricular septal defect				
		Subtricuspid	Subaortic	Doubly committed	Muscular	Unknown
Prolapse of cusp	8	1	2	5	0	0
Bacterial endocarditis	3	1	2	0	0	0
Subaortic stenosis	3	2	1	0	0	0
Unknown	11	6	0	3	1	1
Bicuspid aortic valve	12	4	0	1	4	3
Total	37	14	5	9	5	4

relation to endocarditis or surgery. Associated lesions were present in five patients.

#### *Aortic regurgitation*

Aortic regurgitation developed during observation in 37 patients (19.7%); in 12 there was an associated bicuspid aortic valve. The 25 patients with a once normal tricuspid aortic valve usually had outflow defects beneath the aortic and/or pulmonary valve. In one patient only, the defect was central muscular, but with the addition of a thin, bulging interventricular septum in the subtricuspid region, suggesting there had been an additional defect in this region which had closed spontaneously in childhood. Associated lesions other than the bicuspid aortic valve were present in two patients (one subaortic shelf and one repaired coarctation). Mechanisms of aortic regurgitation are listed in Table 6. Surgery was needed in the three patients with aortic regurgitation due to endocarditis, in one patient with a bicuspid aortic valve and in five patients with a once normal tricuspid aortic valve with or without prolapse.

#### *Subaortic stenosis*

Fixed subaortic stenosis was present in 11 patients age 16 to 42 (mean 25) years, as a crescent ridge (3) or shelf (8). The ventricular septal defect was subtricuspid (5), subaortic (2), doubly committed (3), unknown (1). In two cases, subaortic stenosis was diagnosed after spontaneous closure of the defect and we do not know when the lesion had developed. Obstruction was mild (peak gradient 20–30 mmHg) in all but one case (case 178; peak gradient 105 mmHg).

#### *Electrocardiographic changes*

First-degree heart block was present in four patients with a subtricuspid defect when first seen age 18 to 54 (mean 37) years. One with small subtricuspid defect had congenital complete heart block. Fifteen patients, with additional mild/moderate right ventricular outflow tract obstruction in five, had complete right bundle branch block. This was, or had been, present in 12 patients at their first visit (at age 16–40 years) and developed in three at age 31–45 years, in one case after the defect had closed. Left anterior hemiblock was present in eight

patients with a subtricuspid defect at their first visit, age 16–53 years; two had mitral valve prolapse. One patient with a muscular defect had isolated complete left bundle branch block when first seen at age 18 years, and 12 years later the electrocardiogram was unchanged.

Fifty patients fulfilled the electrocardiographic criteria for left ventricular hypertrophy (voltage criteria of Sokolow, often with ST changes); 26 had associated coarctation of the aorta, subaortic stenosis or significant aortic regurgitation, the other 24 no associated lesions causing left ventricular hypertrophy (Table 7).

#### *Arrhythmias*

Ventricular or supraventricular arrhythmias were documented in 16 patients: two patients had symptomatic frequent ventricular ectopics on Holter monitoring. In two further patients, aged 25 and 45 years, recurrent episodes of ventricular tachycardia, haemodynamically well tolerated, were documented and treated with beta-blockade and/or amiodarone. One had a muscular outlet defect, a bicuspid aortic valve with mild aortic regurgitation, had had coarctation repair in childhood and his left ventricle was dilated (65 mm). The second patient had a subtricuspid defect with extension into the outlet region, moderate pulmonary regurgitation and a dilated right ventricle; when first seen at age 42 years he was asymptomatic and his electrocardiogram showed left anterior hemiblock. Three years later he developed recurrent ventricular tachycardia and wide right bundle branch block (QRS 160 ms); under treatment with beta-blocker and amiodarone the QRS complex widened further (200 ms) with intermittent 2:1 heart block. No ventricular tachycardia recurred in either patient whilst on antiarrhythmic therapy.

Supraventricular arrhythmias were documented in 12 patients with subtricuspid defects. Four patients had episodes of supraventricular tachycardia and eight developed atrial fibrillation (paroxysmal in three and established in five); in only three were there other conditions predisposing to atrial fibrillation (end-stage hypertrophic cardiomyopathy, acquired coronary artery disease, closed atrial septal defect). Atrial fibrillation was haemodynamically poorly tolerated in five patients (see later).

**Table 7** *Electrocardiographic changes*

Abnormal features on ECG	Number of patients	Site of ventricular septal defect				
		Subtricuspid	Subaortic	Doubly committed	Muscular	Unknown
First degree heart block	4	4	0	0	0	0
Left anterior hemiblock+right bundle branch block+second degree heart block	1	1	0	0	0	0
Congenital complete heart block	1	1	0	0	0	0
Right bundle branch block (without right ventricular outflow tract obstruction)	10	8	0	0	1	1
Left bundle branch block	1	0	0	0	1	0
Left anterior hemiblock	8	8	0	0	0	0
Left ventricular hypertrophy (unexplained)	24	19	0	1	1	3

One patient, age 26 years, with a 0.4 cm subtricuspid ventricular septal defect had a bulging aneurysmal large membranous sac 1.5 × 1.2 cm between the attachments of septal and anterosuperior tricuspid leaflets and died suddenly without warning of any symptom. The membranous septum was unusually large (pers. comm. Dr Leon Gerlis) but no abnormality was found in the conducting tissue (pers. comm. Professor R. Anderson and Dr Y. Ho). The medical records revealed he had always had right bundle branch block (0.10 s) and variable atrial arrhythmia, and had one syncopal attack age 11 years related to a reported rapid heart rate but nothing was found on admission to hospital and there was no recurrence.

#### *Features of 'cardiomyopathy'*

With the onset of atrial fibrillation which occurred age 32–69 years, five patients — one aged 44 years (case 102) with added hypertrophic cardiomyopathy, four (cases 100, 141, 156 and 173) without other haemodynamically significant lesions — developed features of severe congestion with ascites and oedema. Conversion to sinus rhythm resulted in dramatic improvement, but atrial fibrillation recurred despite antiarrhythmic therapy and finally became established in two. Small subtricuspid defects were present and after the onset of atrial fibrillation a left ventricular to right atrial shunt was obvious. At the onset of symptoms, ventricular dimensions and function were normal, mild regurgitation of the atrioventricular valves and significant dilatation of the atria were present. Later in three patients the ventricles dilated with impairment of systolic function. The moderately elevated pulmonary artery pressure in three cases was considered to be secondary to left ventricular failure, as the defects were clearly small. Surgical closure in one patient resulted in dramatic improvement. One (case 173), in chronic right heart failure for 10 years, died from Gram-negative septicaemia (Table 8).

#### *Left ventricular abnormality*

Twenty-six patients, without an obvious structural lesion to account for it, had one or more features

suggesting enlargement and dysfunction of the left ventricle; a cardiothoracic ratio greater than 50% (54–74%), an increased end-diastolic diameter of the left ventricle (>55 mm) demonstrated on the echocardiogram, acquired mitral regurgitation with a structurally normal mitral valve, abnormal septal diameter (end diastolic >12 mm) and/or movement (Table 9).

In Table 10 the incidence of the most important complications is compared in the groups with and without associated lesions and the whole cohort. A separate analysis of the complication rate in patients with no associated lesions in the cardiovascular system showed no difference in incidence of infective endocarditis, aortic regurgitation and left ventricular abnormality compared to the whole group; the exception was an increased risk of aortic regurgitation in the presence of a congenitally abnormal aortic valve — bicuspid was the usual anomaly.

## Discussion

This study documents that in patients who reached adult life with a small ventricular septal defect spontaneous closure can occur in any decade; in our group it was observed in 10% or 0.8% per year, similar to other reports<sup>[1,6]</sup>. The mechanism of closure of subtricuspid defects is by apposition of tricuspid valve tissue, with or without formation of a septal aneurysm<sup>[5,6]</sup>, but formation of an aneurysm does not automatically result in complete closure<sup>[6]</sup>. In our series, no muscular defects were documented to close spontaneously in adulthood, although it is likely that some of the defects of unknown localization were muscular and we assume it occurs. Prolapse of an aortic cusp<sup>[1]</sup> diminishes the size of some doubly committed and subpulmonary defects.

Infective endocarditis, occurring in 11%, was the most frequent and serious complication, as also reported in other series<sup>[2,7]</sup>. In this series the incidence may be increased because of referral to a special unit when endocarditis had occurred. The course was frequently aggravated by diagnostic delay and in one third of

**Table 8 Patients with appearance of restrictive cardiomyopathy after onset of atrial fibrillation**

Patient number	Sex	Associated lesions	Age	Symptoms	ECG	CTR (%)	Catheter	Echo	Outcome
100	M	Mild AR	61	congestive failure	AF, LVH	55	—	Small VSD, normal LV+RV dimensions and function, mild AR, dilated LA and RA.	AF relapsed after cardioversion; improvement on anti-failure drugs.
			67	worsening failure	as before	60	LV 116/15 RV 50/15 PA 51/25 M=40 Shunt 1.5:1	LV dilated, poor function, mild AR, dilated LA and RA.	Improved with increased diuretics; sudden death 6 months later after prostatic surgery. No necropsy.
141	M	Mild RVOTO	42	congestive failure	AF, RBBB → SR	73	LV 130/0/24 RV 56/0/24 PA 40/20 M=27 Shunt 2:1	Small VSD, normal LV+RV dimensions and function, mild MR and TR, LA+RA hugely dilated.	Improved after DC cardioversion, AF recurred several times. Age 44: surgical closure of VSD and resection of RVOTO
			45	mild dyspnoea	SR, RBBB	68	—	Normal LV+RV dimensions and function, mild MR+TR, dilated LA+RA.	Much improved, maintaining SR without antiarrhythmic treatment.
156	F	—	54	palpitation (sinus tachycardia)	SR, LAD	55	—	Small VSD, normal LV+RV dimensions and function, normal L.A. trivial MR.	Asymptomatic
			69	congestive failure	AF, LAD → (in SR) P-R=220 ms	66	Ao 130/60 RV 55/6 PA 50/25 M=40 Shunt 1.8:1	Small VSD, normal LV+RV dimensions and function, mild MR, dilated LA+RA	Improved after DC cardioversion, recurrent episodes of AF despite antiarrhythmic therapy.
			72	recurrent episodes of failure	SR, LAD, P-R=220 ms	56	—	Dilated LV with impaired function, mild MR, dilated LA+RA.	Well except during recurrent episodes of AF → congestive failure.
173	M	Small PDA	32	congestive failure, cerebral embolus	AF, RBBB	60	LV 110/13/25 RV 36/6/9 PA 34/14 M=22 Shunt 1.5:1	Thin VSD, normal LV+RV dimensions and function, LA+RA hugely dilated; clot in RA.	Improved after DC cardioversion, recurrent episodes of AF, established AF since age 34 years.
			36	worsening failure severe TR	as before	66	PA 70/36 M=48	No VSD, dilated LV with poor function, hugely dilated atria RA>LA, clot in RA.	Chronic congestive failure. Died age 42 years from Gram-negative septicaemia.

AF = atrial fibrillation, Ao = aorta, AR = aortic regurgitation, CTR = cardiothoracic ratio, LA = left atrium, LAD = left axis deviation, LV = left ventricle, LVH = left ventricular hypertrophy, MR = mitral regurgitation, PA = pulmonary artery, PDA = persistent ductus arteriosus, RA = right atrium, RBBB = right bundle branch block, RV = right ventricle, RVOTO = right ventricular outflow tract obstruction, SR = sinus rhythm, TR = tricuspid regurgitation, VSD = ventricular septal defect.

**Table 9** Small ventricular septal defects — features of left ventricular disease

	Number of patients	Site of ventricular septal defect				
		Subtricuspid	Subaortic	Doubly committed	Muscular	Unknown
↑Cardiothoracic ratio	38 (17)	29 (15)	2 (0)	2 (0)	4 (1)	1 (1)
↑Left ventricular end-diastolic diameter (echo)	27 (11)	15 (9)	1 (0)	6 (0)	5 (2)	0
Functional mitral regurgitation	16	8	0	1	5	2
Flat septum	3	3	0	0	0	0
Subaortic stenosis	11	5	2	3	0	1

( ) = patients without associated lesions which could cause left ventricular enlargement. ↑ = Increased.

**Table 10** Complications in patients with and without associated lesions compared to the whole cohort

Complication	Total Group (n=188)	Patients without associated lesions (n=138)	Patients with associated lesions (n=50)
Endocarditis	21 (11.2%)	16 (11.6%)	5 (10%)
Aortic regurgitation	37 (19.7%)	23 (16.7%)	14 (28%)
Symptomatic arrhythmia	13 (6.9%)	4 (3%)	9 (18%)
'Cardiomyopathy'	4 (2.1%)	1 (0.7%)	3 (6%)
Left ventricular abnormality	26 (13.8%)	20 (14.5%)	6 (12%)

the patients emergency surgery was undertaken for continued infection or associated haemodynamic deterioration. Closure of the defect in childhood would have prevented this complication except where there was already established left atrioventricular valve abnormality — congenital or acquired.

The overall incidence of aortic regurgitation (19.7%) with small ventricular septal defect was similar to other series<sup>[7,8]</sup>. It was severe enough to require surgical treatment in nine patients (4.8%). Twelve patients had a associated bicuspid aortic valve. Other known mechanisms were endocarditis, right or non-coronary cusp prolapse, and subaortic stenosis<sup>[9]</sup>. Eleven patients (44% of cases with aortic regurgitation) appeared not to have any of these mechanisms. Aortic regurgitation was probably caused by an intrinsic abnormality of the aortic sinuses or root associated with outflow subvalvular ventricular septal defects. This would explain why in adults closure of the defect alone did not relieve severe aortic incompetence which always required repair or replacement of the aortic valve<sup>[10]</sup>. Whether surgery in childhood would have prevented the onset of aortic regurgitation is unknown but possible<sup>[11]</sup>.

The relationship between small ventricular septal defect and subaortic stenosis is well documented,<sup>[1,5,12–14]</sup> but whether this relates to a congenital abnormality of the left ventricular outflow tract or acquired changes as the defect closes<sup>[5]</sup> is still speculative and what the abnormality is remains uncertain. Subaortic stenosis may not be detected clinically in the presence of ventricular septal defect<sup>[14]</sup>. With small ventricular

defects various degrees of heart block<sup>[5,15]</sup>, a higher prevalence of ventricular arrhythmias and sudden death<sup>[2,3]</sup> have been reported. Fibrosis occurring during closure of a subtricuspid defect is a likely cause<sup>[2]</sup>. Left anterior hemiblock has been described, developing with closure or reduction in size of subtricuspid defects<sup>[5]</sup>, and occurred in this series, as well as complete right bundle branch block and first degree heart block. In our group, no patient acquired complete heart block although this has been documented<sup>[15]</sup>. Ventricular tachycardia occurred twice in our series; defects were muscular outlet and subtricuspid with extension into the outlet region and both patients had associated left (repaired coarctation and aortic regurgitation) or right-sided lesions (pulmonary regurgitation). It is likely that significant dilatation of the left or right ventricle was at least one pro-arrhythmogenic factor. Supraventricular arrhythmias, occurring in subtricuspid defects, were the most common arrhythmic complications we observed. Atrial fibrillation had disastrous effects in producing features of severe tricuspid regurgitation with right heart failure<sup>[5]</sup>. Although conversion to sinus rhythm brought important haemodynamic improvement, atrial fibrillation often recurred and once established left the patient in chronic failure. Echocardiographically the characteristic features at the onset of symptoms — huge dilation of both atria, mild mitral and tricuspid regurgitation, normal ventricular dimensions with preserved function — suggested restrictive physiology. Whether a form of cardiomyopathy was present or it was a mechanical effect of left ventricular to right atrial shunting is unknown. The considerable clinical improvement after

surgical closure of the defect in one patient suggests that early surgery could have prevented deterioration.

Left ventricular dilatation on echocardiography<sup>[2]</sup>, reduced left ventricular function on exercise<sup>[16]</sup> and subnormal working capacity and fractional shortening<sup>[17]</sup> are reported with small ventricular septal defects. A 'ventricular septal defect cardiomyopathy' was postulated by Bloomfield in 1964<sup>[1]</sup>. Recalling a report of increased incidence of congestive heart failure in patients with small ventricular septal defects<sup>[18]</sup>, the author suggested an increased susceptibility to left ventricular disease, especially in the presence of hypertension or ischaemic heart disease; the defective septum was postulated to be unable to make its normal contribution to contraction, increasing the strain on the lateral wall, thus facilitating development of ventricular disease. Others believe a long-standing ventricular septal defect may lead to disturbed systolic function and increase of compliance of both ventricles via a chronic pressure and volume overload<sup>[17]</sup>. In our study, left ventricular disease was suggested by radiological and echocardiographic findings in a subgroup of patients. We think left ventricular disease occurs in patients with small ventricular septal defects, as part of diffuse congenital cardiovascular disease and unrelated to the actual defect. We find the other mechanisms unacceptable when the defect has been established as small over many decades. The presence of dysplastic cardiac muscle is a likely cause<sup>[5]</sup> and variable or no clinical features are possible.

Two limitations in this study exist. First the difficulty of accurately classifying a ventricular defect as 'small' by reproducible and reliable criteria when no cardiac catheter has been performed. It is questionable whether asymptomatic patients with defects that are too small to establish by non-invasive criteria and experienced clinical evaluation should have an invasive diagnostic examination. Thus we chose to include patients with defects judged as 'small' by commonly accepted clinical and non-invasive diagnostic criteria. The second limitation is the inclusion in the study of patients with associated lesions; in a number of cases it will remain unclear whether complications were favoured by the additional lesion. In this group aortic regurgitation, infective endocarditis and left ventricular abnormalities appeared equally frequent in a separate analysis of the subgroup without associated lesions, whereas arrhythmias and restrictive physiology might be less common in the absence of other lesions. However, the small numbers of patients does not allow definitive conclusions.

## Conclusion

The course of small ventricular septal defects appears not entirely benign. The incidence of important complications (infective endocarditis, severe aortic regurgitation, symptomatic arrhythmia, frank heart failure) was 24.5% over 13 years, although it is accepted that there is a selection bias towards the complications in this

series. Bacterial endocarditis is still a serious risk to be aware of and atrial arrhythmias become more frequent after the age of 40 years and can cause important deterioration. In this series, muscular defects, smaller in number, had a significantly lower incidence of complications. Surgical closure in childhood would decrease the incidence of bacterial endocarditis and possibly the development of aortic regurgitation and arrhythmias.

## References

- [1] Bloomfield DK. The natural history of ventricular septal defect in patients surviving infancy. *Circulation* 1964; 29: 914-55.
- [2] Otterstad JE, Erikssen J, Michelsen S, Nitter-Hauge S. Long-term follow-up in isolated ventricular septal defect considered too small to warrant operation. *J Int Med* 1990; 228: 305-9.
- [3] Kidd L, Driscoll DJ, Gersony WM *et al.* Second natural history study of congenital heart defects. Results of treatment of patients with ventricular septal defects. *Circulation*. 1993; 87(2 Suppl): 138-51.
- [4] Capelli H, Andrade JL, Somerville J. Classification of the site of ventricular septal defect by 2-dimensional echocardiography. *Am J Cardiol* 1983; 51: 1474-80.
- [5] Somerville J. Congenital heart disease — changes in form and function. *Br Heart J* 1979; 41: 1-22.
- [6] Beerman LB, Park SC, Fischer DR *et al.* Ventricular septal defect associated with aneurysm of the membranous septum. *J Am Coll Cardiol* 1985; 5: 118-23.
- [7] Otterstad JE, Nitter-Hauge S, Myhre E. Isolated ventricular septal defect in adults. Clinical and haemodynamic findings. *Br Heart J* 1983; 50: 343-8.
- [8] Otterstad JE, Ihlen H, Vatne K. Aortic regurgitation associated with ventricular septal defects in adults. Clinical course, haemodynamic, angiographic and echocardiographic findings. *Acta Med Scand* 1985; 218: 85-96.
- [9] Blumenthal S, Kangos JK, Bowman FO *et al.* Ventricular septal defect with prolapse of the aortic cusp (Abstr). *Circulation* 1963; 28: 691.
- [10] Somerville J, Brandao A, Ross, DN. Aortic regurgitation with ventricular septal defect. *Circulation* 1970; 41: 317-30.
- [11] Backer CL, Winters RC, Zales VR *et al.* Restrictive ventricular septal defect: how small is too small to close? *Ann Thor Surg* 1993; 56: 1014-9.
- [12] Chung KJ, Fulton DR, Kreidberg MB, Payne DD, Cleveland RJ. Combined discrete subaortic stenosis and ventricular septal defect in infants and children. *Am J Cardiol* 1984; 53: 1429-32.
- [13] Silverman NH, Gerlis LM, Ho SY, Anderson RH. Fibrous obstruction within the left ventricular outflow tract associated with ventricular septal defect: a pathologic study. *J Am Coll Cardiol* 1995; 25: 475-81.
- [14] Fisher DJ, Snider AR, Silverman NH, Stanger P. Ventricular septal defect with silent discrete subaortic stenosis. *Paediatr Cardiol* 1982; 2: 265-9.
- [15] Smith NM, Ho SY. Heart block and sudden death associated with fibrosis of the conduction system at the margin of a ventricular septal defect. *Paediatr Cardiol* 1994; 15: 139-42.
- [16] Jablonsky G, Hilton D, Liu PP *et al.* Rest and exercise ventricular function in adults with congenital ventricular septal defects. *Am J Cardiol* 1983; 51: 293-8.
- [17] Otterstad JE, Simonsen S, Erikssen J. Hemodynamic findings at rest and during mild supine exercise in adults with isolated, uncomplicated ventricular septal defects. *Circulation* 1985; 71: 650-62.
- [18] Selzer A. Defect of the ventricular septum: Summary of the twelve cases and review of the literature. *Arch Int Med* 1949; 84: 798.