
Working Group Report

A classification of atrial flutter and regular atrial tachycardia according to electrophysiological mechanisms and anatomical bases

A Statement from a Joint Expert Group from the Working Group of Arrhythmias of the European Society of Cardiology and the North American Society of Pacing and Electrophysiology

N. Saoudi, F. Cosío, A. Waldo, S. A. Chen, Y. Iesaka, M. Lesh, S. Saksena, J. Salerno and W. Schoels

Background and motives

Current classifications of regular atrial tachycardias have been based exclusively on the ECG. Differentiation between atrial flutter and atrial tachycardia depends on a rate cut-off around 240–250/min and the presence of isoelectric baselines between atrial deflections in atrial tachycardia, but not in atrial flutter^[1,2]. However, atrial tachycardia mechanisms, defined by electrophysiological studies and radiofrequency catheter ablation, do not correlate with electrocardiographic (ECG) patterns as defined currently, and a certain amount of confusion is evident in the literature at the time of assigning appropriate terms to specific arrhythmias.

The current ECG classification is obsolete for this purpose, creating the need for a mechanistic classification of atrial tachycardias. Terms and definitions employed were not very important when only electrical cardioversion and/or empirical antiarrhythmic drug therapy were available. Unfortunately, knowledge of the electrophysiological properties of the atrial tachycardia mechanism is still too incomplete to guide antiarrhythmic drug choice, and selective drugs are not available to effectively target each tachycardia mechanism and component. However, radiofrequency ablation offers specific

treatment, targeted to the anatomical substrate. To guide the clinical cardiologist and for better communication between electrophysiologists, it has become necessary to clarify the relationship between the traditionally used terms atrial flutter and atrial tachycardia and the underlying mechanism of arrhythmia, including its anatomical bases.

To attain this goal, an Expert Group was appointed jointly by The Working Group of Arrhythmias of the European Society of Cardiology and the North American Society of Pacing and Electrophysiology to draft a proposal for a new classification of atrial tachycardias. The latter is based on electrophysiological findings, in order to match present understanding of mechanisms and therapy of these arrhythmias, and is directed at electrophysiologists as well as clinical cardiologists with interests in arrhythmias. Arrhythmia involving extra-atrial tissue such as atrioventricular node reentry or atrioventricular reciprocating tachycardia will not be included in this classification.

Proposal for a classification

We see this proposal as a bridge between old classifications based on the ECG and present knowledge of mechanisms. In so far as not all atrial tachycardia mechanisms are clearly known, a closed, seemingly complete classification could be deceptive. In this work, we would like to express our vision of atrial flutter and tachycardia as well as the limits of this understanding. Given the rapid development of knowledge and technology it is likely that after publication some of the questions here posed may have been answered. However, an open classification will be able to accommodate new information.

Key Words: Classification, flutter, atrial tachycardia, macroreentrant tachycardia, focal tachycardia, mapping, entrainment.

Manuscript submitted 11 February 2001, and accepted 15 February 2001.

Correspondence: Nadir Saoudi, MD, Professor of Cardiology, BP No 489, Centre Hospitalier Princesse Grace, Avenue Pasteur, 98012 Monaco (Principauté).

Two types of atrial tachycardia are relatively well known and can be defined clearly on the bases of their electrophysiological mechanisms:

- Focal atrial tachycardia (due to an automatic, triggered, or microreentrant mechanism).
- Macroreentrant atrial tachycardia (including typical atrial flutter and other well characterized macroreentrant circuits in right and left atrium).

Other tachycardias described in the literature cannot always be well classified because of inadequate understanding of mechanism(s). These will be discussed:

- Atypical atrial flutter
- Type II atrial flutter
- Inappropriate sinus tachycardia
- Reentrant sinus tachycardia
- Fibrillatory conduction

It should be understood that the weight of tradition makes difficult a departure from currently used terms. Thus the term flutter will refer to a continuously waving pattern on the ECG, without an isoelectric baseline in at least one lead, whatever the cycle length. Notwithstanding, the presence or absence of an isoelectric baseline contributes little to the underlying mechanism, with the exceptions that will be pointed out. A detailed morphological description of the ECG will be used in each case to help avoid confusion.

Basis for electrophysiological diagnosis

Diagnostic tools

Activation mapping, the response to pacing and knowledge of any anatomical abnormalities, such as surgical scars, are the electrophysiological tools that allow definition of arrhythmia mechanisms^[3–10]. In a clinical electrophysiological setting, bipolar recordings with a short inter-electrode distance (≤ 2 mm) offer sufficient spatial resolution for most mapping, as reentrant circuit size is generally large (several cm in diameter). Distances between mapped sites of 0.5–1.0 cm are the best resolution currently attainable, but this is enough for the diagnosis of most clinical atrial tachycardias.

It is acknowledged that the limitations of atrial mapping as well as tachycardia definition include the inaccessibility of some endocardial atrial recording sites as well as the inability to map the mid-myocardium and epicardium using traditional catheter electrode techniques. Unipolar mapping may add significant information in selected situations. It has also been suggested that a monophasic action potential catheter could help by recording delayed afterdepolarizations from atrial tissues with triggered activity^[11].

Electrical activity can often be recorded during the presence of an isoelectric baseline in the ECG during endocardial mapping. This is a significant contribution of mapping to understanding atrial tachycardia mech-

anisms. Complete endocardial activation mapping can be readily performed in the right atrium. Left atrial mapping requires a transeptal puncture in most cases. Coronary sinus activation mapping only reflects activation of a small portion of the left atrium. Oesophageal electrodes may also be used to determine activation of the posterior left atrium^[2]. Because of these limitations the left atrial activation sequence is not well characterized in many atrial tachycardias.

Recent new technologies have provided additional or corroborative data. These are the non-contact mapping system and the electro-anatomical contact mapping system. In the first, a catheter-based multi-electrode array is connected to an amplifier system and a work station to reconstruct more than 3000 simultaneous electrograms. These are displayed as standard electrogram traces, and translated into a 3D graphical representation of the heart chamber in an isochronal or isopotential mode^[12,13]. The other system includes a sensor-equipped mapping and ablation catheter, a location pad, a processor and a work station. The location pad itself incorporates three pods mounted on a triangular frame attached to the underside of the fluoroscopy table, and emits a weak electromagnetic field, allowing the catheter sensor to be localized in the electromagnetically coded space^[14,15]. Both techniques allow a far better spatial resolution, and have dramatically enhanced mapping precision.

Transient entrainment, studied both in the ECG and with multiple simultaneous intra-atrial recordings, is of help, as a complement to activation mapping, to diagnose reentrant mechanisms^[16–18]. Fusion during entrainment will be recognized in the ECG by a partial change in atrial deflections, intermediate between baseline atrial tachycardia morphology and the morphology produced by pacing during sinus rhythm at the same site (Fig. 1). Collision of activation fronts and/or a partial change in the activation sequence detected by multiple simultaneous endocardial recordings, is the surrogate of fusion in the surface ECG^[5,6,19,20] (Fig. 2). This can overcome the difficulties of recognizing fusion patterns during entrainment, posed by low voltage of atrial deflections on the ECG and/or QRS complex and T wave overlap.

Drug effects can be helpful in particular situations; however, they are not totally specific in the diagnosis of atrial tachycardia mechanisms^[21].

Basic mechanisms of arrhythmia

Arrhythmias have often been classified according to their basic mechanisms. Although not directly relevant to the classification proposed in this paper, this statement certainly accepts the classic definitions of reentry, triggered activity, and automaticity using accepted criteria.

Reentry is usually confirmed by demonstrating initiation and termination of atrial tachycardias with programmed electrical stimulation and by the presence of

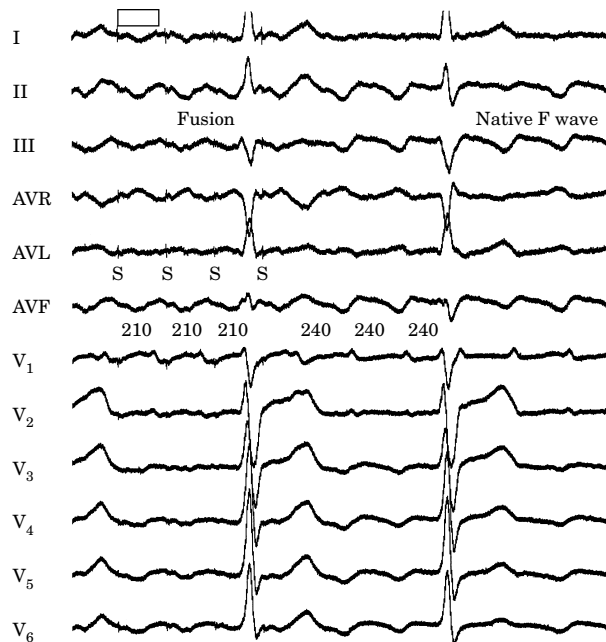


Figure 1 Twelve lead ECG of typical atrial flutter entrainment. Pacing of the left atrium is initiated during ongoing atrial tachycardia via the distal portion of the coronary sinus. Baseline atrial flutter cycle length was 240 ms. During pacing at a 210 ms cycle length, there is constant atrial capture. The atrial deflections remain mainly negative, although less so than at baseline (fusion). Changes of the paced and entrained atrial flutter waves are clearly visible in lead I, V₁ and the inferior leads. In this and subsequent figures, S represents pacing artifacts.

manifest or concealed entrainment. It is associated with anatomical or functional regions of block as well as areas of slow conduction^[22–25].

Enhanced and abnormal automaticity cannot be initiated or terminated with programmed electrical stimulation. Both are usually provokable after administration of intravenous isoproterenol^[26]. Pacing of enhanced automaticity is followed by post overdrive suppression.

Tachycardia related to triggered activity have been less well defined^[27,28]. Pacing manoeuvres may result in post overdrive acceleration. In the human ventricle, verapamil has been shown to suppress arrhythmia thought to be due to triggered activity^[29,30]. Due to the lack of a reliable means of identifying these mechanisms in the electrophysiological laboratory, classification solely on the basis of mechanisms is clinically very difficult if not impossible, and currently is often clinically useless. Thus, it will not be used in this proposal, but will be addressed in each relevant situation.

Focal atrial tachycardia

Mechanisms

Focal atrial tachycardia is characterized by atrial activation starting rhythmically at a small area (focus)

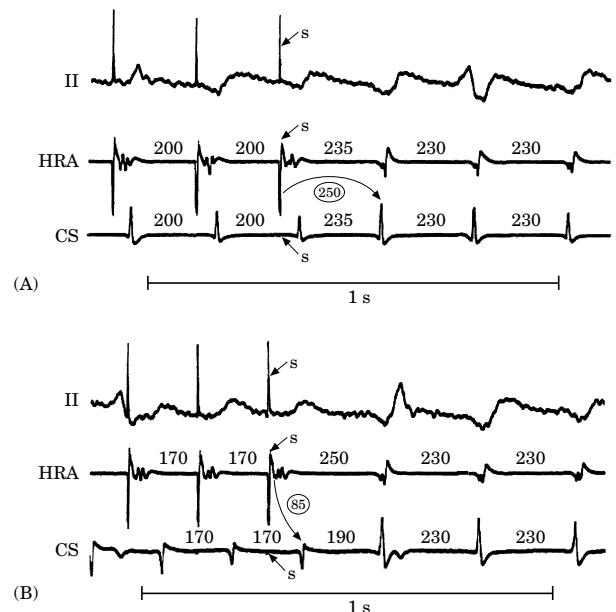


Figure 2 Surrogate fusion in the surface ECG during transient entrainment. ECG lead II is recorded simultaneously with electrograms from the high right atrium and the coronary sinus during pacing at cycle lengths of 200 ms (A) and 170 ms (B) during atrial flutter with a spontaneous cycle length of 230 ms. In A, during the period of constant pacing, conduction time (curved arrow) from the pacing site to the coronary sinus atrial electrogram is 250 ms (encircled number) and the coronary sinus atrial electrogram morphology is similar to that during spontaneous atrial flutter. In B, the conduction time is now 170 ms, and the electrogram morphology is dissimilar to that during spontaneous atrial flutter. The change in conduction time and electrogram morphology during pacing at two different cycle lengths compared to that of tachycardia identifies the intracardiac equivalent of surface ECG fusion. From ref [20] with permission.

from where it spreads centrifugally^[21,31–34]. Frequent locations of such foci are the crista terminalis and the pulmonary veins^[35–37]. When a focus is located high in the crista terminalis, the atrial activation sequence will not be very different from that during sinus rhythm or inappropriate sinus tachycardia. Only sharp changes in rate with minor, but significant changes in origin of activation detected by endocardial mapping permit diagnosis^[37]. Multiple atrial tachycardia foci have been described, and can be a cause of recurrence after surgical or radiofrequency ablation^[38,39].

Available information suggests that focal activity can be due to automaticity, triggered activity (afterpotentials) or reentry^[21]. Atrial tachycardia cycle length is usually ≥ 250 ms. However, it can be as short as ≤ 200 ms. Over a prolonged period of observation (minutes to hours), atrial tachycardia cycle length can exhibit important variations. A progressive rate increase at tachycardia onset (warm up)^[40] and/or a progressive rate decrease before tachycardia termination (cool down)

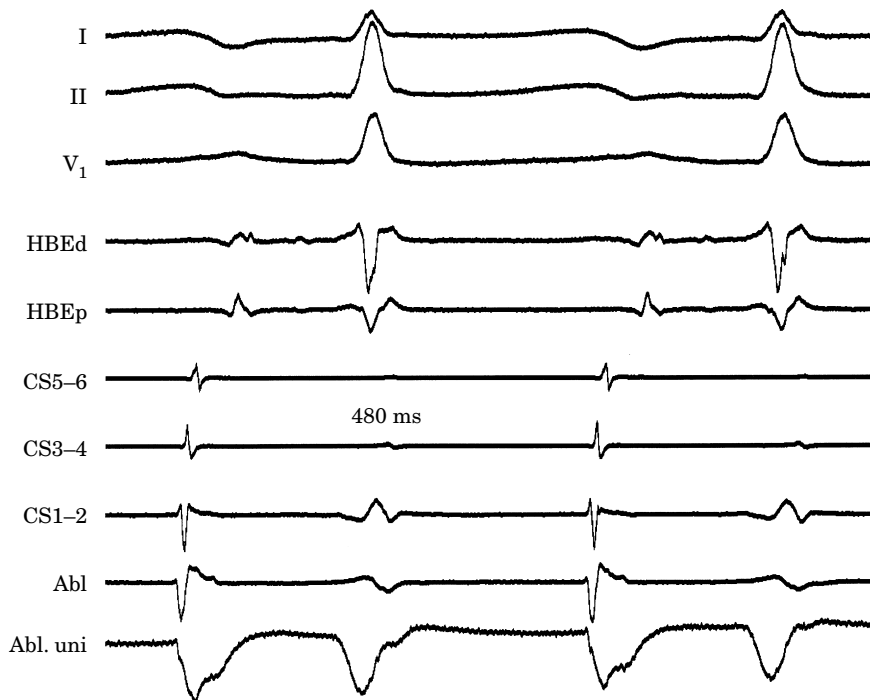


Figure 3 Multiple electrograms in focal atrial tachycardia. In this example of left atrial tachycardia, with a cycle length of 480 ms, recordings are depicted from the mid (CS5-6) to the distal coronary sinus (CS1-2), and the proximal (HBEP) and distal (HBEd) bipoles of the His bundle recording catheter positioned in the right atrium. The site of tachycardia origin is labelled Abl and the corresponding unipolar electrogram locally shows a pure QS pattern. After the impulse has propagated rapidly in all parts of both atria, an electrical silence follows until the next focal atrial discharge.

are suggestive of an automatic mechanism. Rate can increase during exercise^[41,42]. Typically, adrenergic stimulation can accelerate the rate of focal discharge. Relatively small reentry circuits may resemble focal atrial tachycardia, especially if a limited number of endocardial recordings are collected. This point will be further discussed later.

Mapping

Endocardial mapping can trace the origin of activation to a specific area, from where it spreads centrifugally to both atria (Fig. 3). Unipolar recordings will be helpful by showing negative (QS) patterns with sharp initial deflections at the location of the focus. Spread of activation from the focus or origin may not be uniformly radial, as conduction can be directed by anatomical or functional pathways and barriers^[43]. There is generally an electrically silent period in atrial cycle length that, in the ECG, is reflected by an isoelectric line between atrial deflections. Intra-cardiac mapping will show significant portions of the cycle length without recorded activity, even when recording from the entire right atrium, left atrium and/or coronary sinus (Fig. 3). However, in the presence of complex intra-atrial conduction distur-

bances, intra-atrial activation may extend over a large proportion of the cycle length^[43], and conduction spread may follow circular patterns suggestive of macro-reentrant activation.

Even if transient entrainment can occur in some cases, suggesting a reentrant mechanism, constant or progressive fusion^[21], as demonstrated by intermediate wave morphologies on the ECG, cannot be demonstrated. Collision of activation fronts and/or partial activation change during entrainment cannot be demonstrated with multiple endocardial recordings.

ECG pattern

Typically there are discrete P waves at rates 130–240 beats \cdot min⁻¹, but possibly as low as 100 beats \cdot min⁻¹ or as high as 300 beats \cdot min⁻¹. There is a clearly defined isoelectric baseline between P waves in all leads (Fig. 4). P wave morphology will depend on focus location, and it can be used to approximately localize it before electrophysiological study^[36]. It has been suggested that the multilead body surface potential recording can also be used to help localize the site of origin of the tachycardia^[44]. During electrophysiological study, ventricular pacing may help by removing QRS complexes which are superimposed on atrial activity. Adenosine infusion to provide transient increased

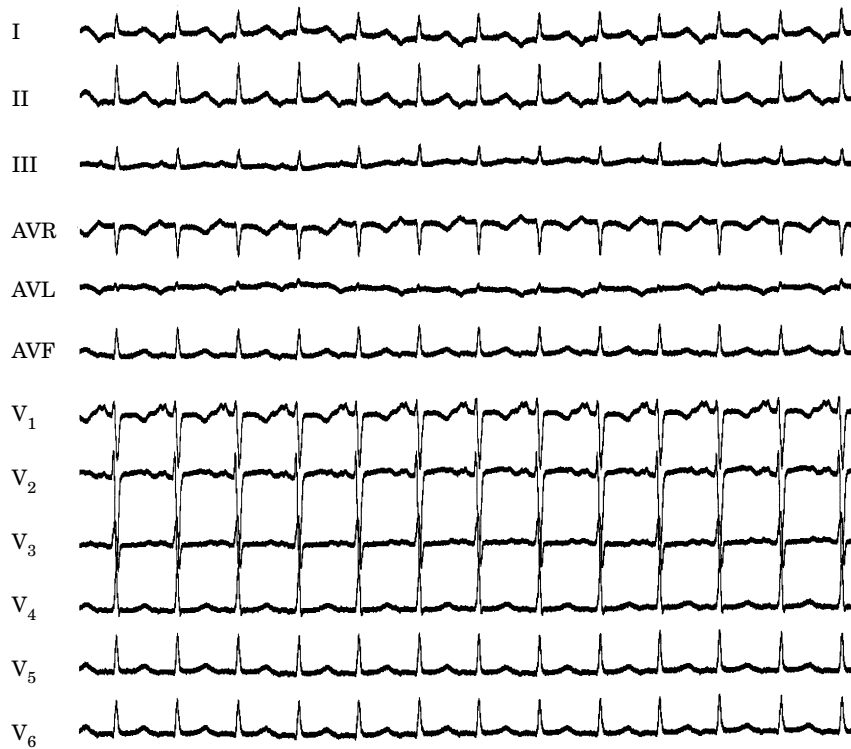


Figure 4 ECG of a focal left atrial tachycardia. In this example of a 16-year-old girl, focal left atrial tachycardia with a cycle length of 480 ms originates in the lateral wall of the left atrium. P waves are negative in the lateral leads and lead II, but positive in leads III and V₁.

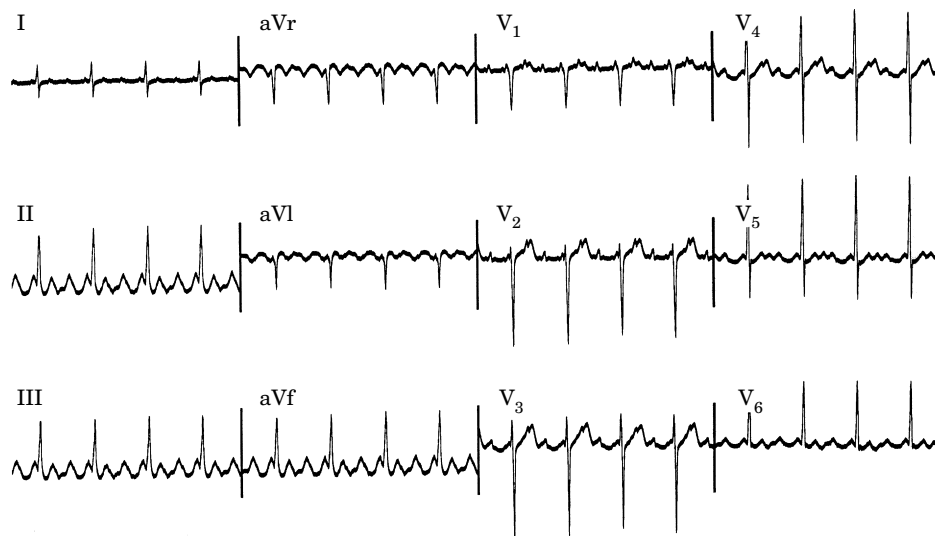


Figure 5 Focal atrial tachycardia presenting with an atrial flutter pattern. In this example of atrial tachycardia, the impulse originates in a left atrial focus, but due to the rapid rate of discharge (240 ms) and possible associated intra-atrial conduction disturbances, exhibits an atrial flutter pattern in the 12-lead ECG.

atrioventricular block can be used to obtain a clear view of the P wave, assuming that the tachycardia does not terminate. In the presence of rapid rates and/or intra-atrial conduction disturbances, P waves can be very

broad, and there may be no isoelectric baseline (Fig. 5). In these cases, the ECG will show an atrial flutter pattern (continuous undulation without isoelectric baseline).

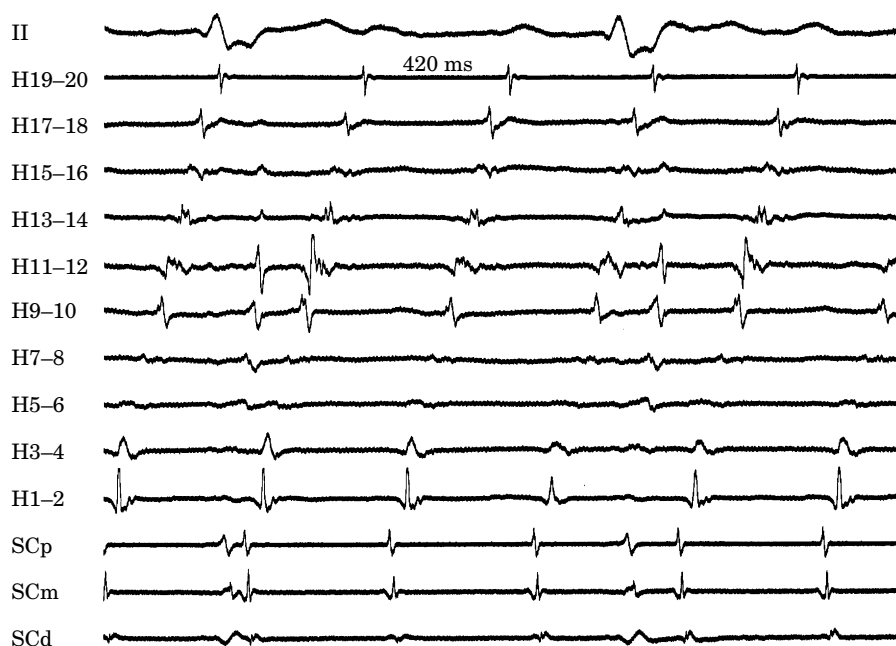

Figure 6 Macroreentrant right atrial tachycardia with a very long cycle length. In the late post operative period after atrial septal defect closure, right atrial reentry with a cycle length of 420 ms occurs with the impulse rotating within a protected isthmus which is limited anteriorly by the tricuspid annulus and posteriorly by the atriotomy scar. Note that the electrical activity is recorded continuously even during the electrically silent period of the surface ECG.

Macroreentrant atrial tachycardia

Mechanisms

The mechanism of macroreentrant atrial tachycardia is reentrant activation around a 'large' central obstacle, generally several centimeters in diameter, at least in one of its dimensions. The central obstacle may consist of normal or abnormal structures. The obstacle can be fixed, functional or a combination of each. There is no single point of origin of activation, and atrial tissues outside the circuit are activated from various parts of the circuit. A description of macroreentrant atrial tachycardia mechanisms must be made in relation to atrial anatomy, including a detailed description of the obstacles or boundaries of the circuit and the critical isthmuses that may be targets for therapeutic action.

The rate range of macroreentrant atrial tachycardia cycle length is too wide to be used as a reliable predictor of the mechanism. Typical atrial flutter, the most common macroreentrant atrial tachycardia, usually has a cycle length between 190 and 250 ms, with $\leq 2\%$ cycle-to-cycle variation^[3,45]. However conduction delays within the circuit can prolong the atrial tachycardia cycle length, making it overlap with the classical focal atrial tachycardia range (>400 ms cycle length) (Fig. 6). This is particularly evident in typical atrial flutter recurring after radiofrequency ablation and in atriotomy macroreentrant atrial tachycardia.

Mapping

The reentry circuit includes large portions of the atria, where continuous, reentrant activation can be recorded with detailed mapping. Activation should be recorded continuously throughout the atrial tachycardia cycle length if atrial mapping is complete. Endocardial recordings will often show activation during isoelectric intervals in the ECG (Fig. 6). The concept of early activation is not applicable to any particular site in the circuit. Activation can be continuously mapped, and an 'earlier' activation time can always be found for any particular point of the circuit. For illustrative purposes, a particular reference point may be designated as the origin of activation (time 0), but it should be understood that this is always arbitrary^[7,8]. Complex surgical procedures, such as the atrial baffle procedure (Mustard, Senning), can render large parts of the atria inaccessible to an exploring electrode catheter, making it impossible to record activation throughout the cycle length.

Lines of block directing activation, either functional (crista terminalis)^[4-6] or fixed (atriotomy, eustachian ridge)^[7,9,10] are reflected by recording double potentials (Fig. 7). Double potentials express sequential activation on both sides of the line of block. However, double potentials can also be recorded from areas of local block outside the reentrant circuit. The interpretation of double potentials has to be made in the context of the general activation sequence and the response of the

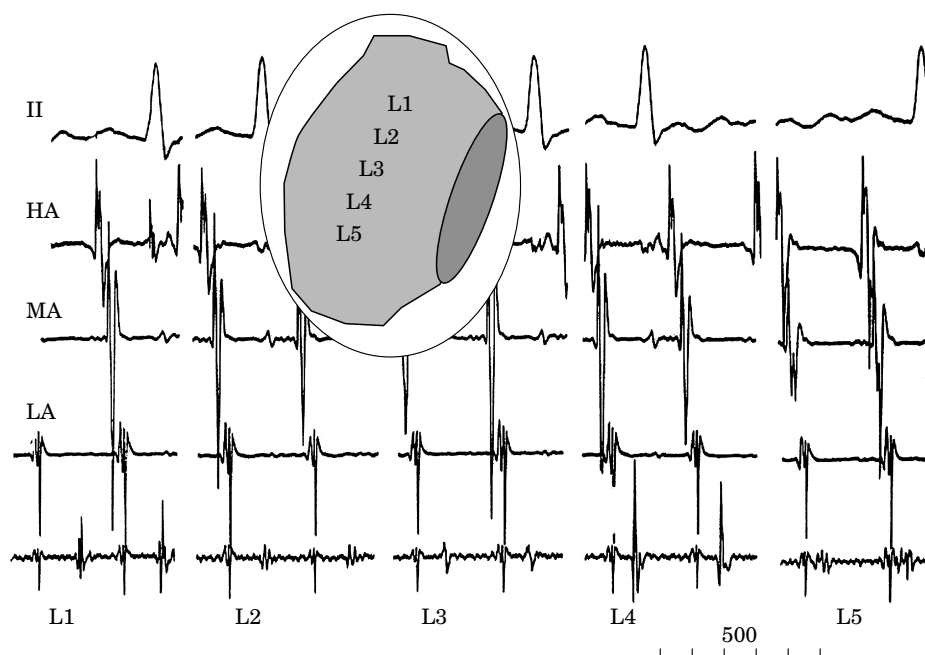


Figure 7 Double electrograms along a line of block. Double electrograms recorded from the centre of the circuit in a patient with scar macroreentrant tachycardia in the lateral right atrium. The superimposed schema represents a right anterior oblique view of the right atrium, and the clear band represents the scar. The five tracings show recordings of lead II and electrograms from the high anterior (HA), the mid anterior (MA) and the low anterior (LA) right atrium. The bottom recording in each trace shows double electrograms along the scarred area from superior to inferior, as marked in the schema. Note the decreasing separation of the electrogram components that become a continuous fractionated electrogram close to the inferior vena cava (L5), suggestive of local slow conduction.

potentials to pacing (entrainment)^[5,6,9,10,46]. Local second-degree block within a composite (≥ 2 components) electrogram identifies a local dead-end pathway, not essential for tachycardia mechanism (Fig. 8). Multiple component (fractionated) electrograms may be recorded at sites of local conduction disturbances and/or slow conduction^[47]. Voltage mapping may be useful in post surgical atrial tachycardia and in patients with significant atrial disease. Areas of low or absent local electrogram amplitude in the bipolar mode represent scar or patch material. Knowledge of such areas helps to determine the possible anatomical circuits.

Transient entrainment

Transient entrainment is possible in the vast majority of cases. Some circuits are very unstable and pacing cycle length should be as close as possible to baseline cycle length in these cases.

When fusion is not discernible in the surface ECG, its equivalent, collision of activation fronts and/or localized activation change, can be detected with the use of multiple recordings from sites chosen strategically in relation to the pacing site and reentry circuit 20 (Fig. 9).

A return cycle length equal to (or within 20 ms of) the atrial tachycardia cycle length at the site of pacing

identifies a site which is part of the reentrant circuit (Fig. 10). Macroreentry is confirmed if exact return pauses (0–20 ms difference from the baseline cycle length), are recorded from at least two atrial pacing sites, separated by at least 2 cm^[17,48]. The entrainment cycle length should be of sufficient length to prolong conduction, which would result in a prolonged return cycle length, even when pacing from within the circuit (Fig. 9). On the other hand, a very long entrainment cycle length makes it harder to recognize fusion/endocardial activation change.

The best characterized macroreentrant atrial tachycardias are typical (or isthmus dependant) atrial flutters and atriotomy (or incisional) atrial tachycardia. Left atrial macroreentrant atrial tachycardia are less well known due to the need for transeptal catheterization for left atrial mapping.

Typical atrial flutter

This is the most common type of macroreentrant atrial tachycardia, even in patients who have undergone cardiac surgery with a right atriotomy^[49]. In typical atrial flutter, activation of the right atrium is reentrant, bounded anteriorly by the tricuspid orifice, and posteriorly by a combination of anatomical obstacles (orifices

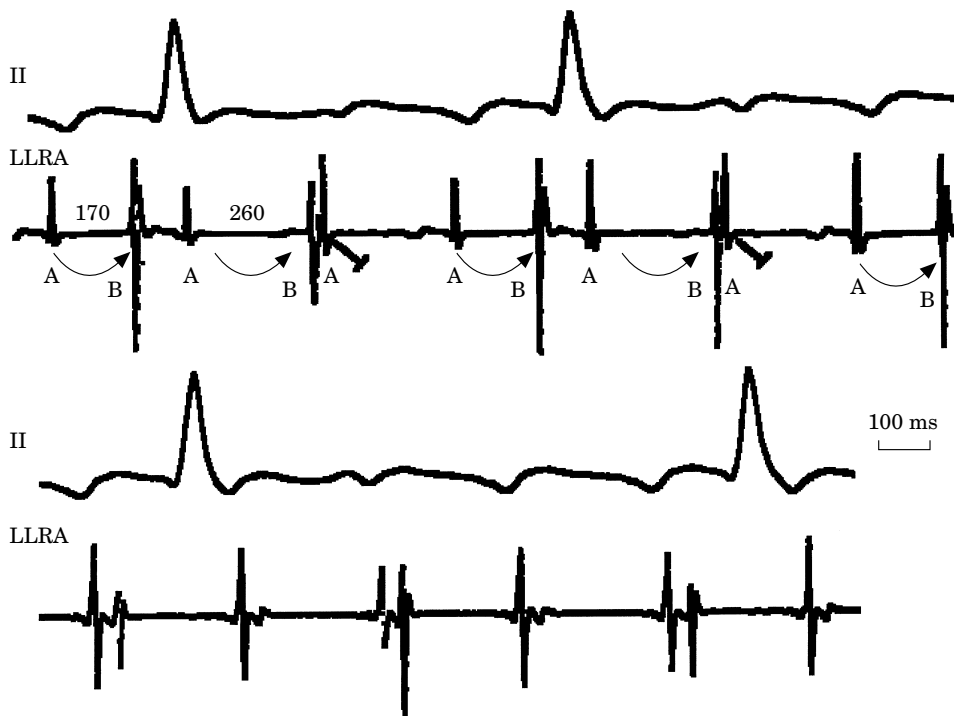


Figure 8 Local intra-electrogram block. Mapping during typical atrial flutter in a patient with severe local intra-atrial conduction disturbances. In the upper panel, within a limited area in the low lateral right atrium region (LLRA), a reproducible pattern of local block is observed between the two components of a double potential electrogram. These are labelled A and B. The distance between the two components of the first double potential electrogram is 170 ms. The interval between A and B increases to 260 ms in the second double potential electrogram. The third electrogram is comprised only of its A component. In this sequence a 3:2 Wenckebach pattern of block occurs between A and B as marked by the arrows. Despite the intermittent lack of the second component of the double potential electrograms, atrial tachycardia remain unperturbed as evidenced by the stability of the AA cycle length which is identical to the atrial flutter cycle length. This shows that this second component is not necessary to the atrial flutter maintenance. Therefore it is the image of a local dead end pathway of activation. A similar phenomenon is shown in the lower panel where a 2:1 block now occurs between the two components of the double potential electrogram at a slightly distant site.

of the superior and inferior vena cava and the eustachian ridge) and functional barriers (the region of the crista terminalis)^[3–6,9,10,50]. Transverse block may be fixed in some patients and of a functional nature in others^[51,52], and occurs in the region between the venae cavae perhaps due to anisotropy. Double potentials are recorded at multiple levels in the region of the crista terminalis^[5,6,9].

The most common direction of activation in the circuit (90% of clinical cases) is in the descent in the case of anterior and lateral walls and in the ascent in the septal and posterior walls of the right atrium. This has been described as counterclockwise reentry, when viewed from a left anterior oblique, fluoroscopic perspective. The opposite direction of activation, descending the septum and ascending the anterior (clockwise reentry) occurs in 10% of clinical cases and characterizes reverse typical atrial flutter (see below).

The superior pivot point is not well defined. Current data suggest that in most cases it includes the

right atrial roof anterior to the superior vena cava orifice, including the initial portions of Bachmann's bundle^[53–55]. However, there is information suggesting that in some cases, activation can also cross the superior end of the crista terminalis^[56] or even lower along this structure^[57]. The inferior pivot point is the area bounded anteriorly by the inferior part of the tricuspid orifice, and posteriorly by the inferior vena cava orifice and its continuation in the eustachian ridge. Double potentials are also recorded along the eustachian ridge^[9,10]. This area has been called the inferior vena cava–tricuspid isthmus, sub-eustachian isthmus, inferior isthmus, or simply flutter isthmus. Complete transection or ablation of this isthmus interrupts and prevents typical atrial flutter^[7,58–60].

Concealed entrainment (no fusion in the surface ECG) can be produced by pacing the inferior isthmus (Fig. 10), but also areas of the low posterior right atrial wall^[7,61]. Localized activation change can be detected by multiple endocardial recordings, even in the absence of

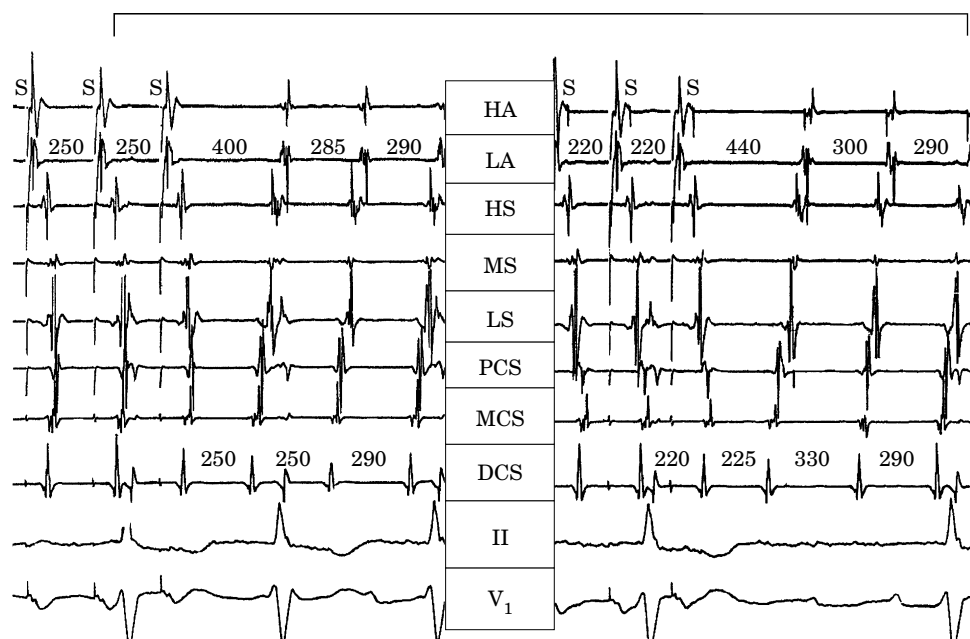


Figure 9 Entrainment of left atrial macroreentrant tachycardia by pacing the mid anterior right atrium. From top to bottom recordings from the high anterior (HA), low anterior (LA), high septal (HS), mid septal (MS) and low septal (LS) right atrial and proximal (PCS), mid (MCS) and distal (DCS) coronary sinus and ECG leads II and V_1 . The left panel shows the end of entrainment at 250 ms cycle length, and the right panel at 220 ms cycle length. The baseline activation sequence, which recurs after pacing, shows coronary sinus activation from distal to proximal preceding the septal right atrium. Anterior right atrial activation occurs last. During pacing, septal activation is reversed. Pacing cycle length 250 (left panel) advances PCS relative to MCS. Pacing cycle length 220 (right) advances PCS further and changes the morphology of MCS, indicating collision of paced and reentrant activation at this site. After pacing at 250 ms cycle length, the return cycle length is equal to the baseline at DCS, but long in all right atrial sites. Pacing at cycle length of 220 ms results in a prolonged return cycle length at DCS, suggesting pacing-induced conduction delay in the circuit. Note the ECG pattern of P waves with isoelectric baselines in V_1 .

fusion in the surface ECG^[5,9,20,62]. A return cycle length after transient entrainment is equal to baseline cycle length (<20 ms difference) when pacing the flutter isthmus, right atrial roof and anterior and septal right atrial walls^[10,53,63].

ECG pattern

A characteristic ECG 'sawtooth' pattern is present in leads II, III and/or aVF (Figs 1 and 11). This consists of a downsloping segment, followed by a sharper negative deflection, then a sharp positive deflection with a positive 'overshoot' leading to the next downsloping plateau. The relative size of each component can vary markedly. Lead V_1 often shows a positive deflection, but biphasic or negative deflections can be seen in some cases. Leads I and aVL characteristically show low voltage deflections.

Reverse typical atrial flutter

A reverse direction of rotation (ascending the anterior wall and descending the posterior and septal walls) can

occur clinically in the typical atrial flutter circuit in 10% of cases^[2,64]. This is still called typical atrial flutter because the reentry path is the same, even though the direction of activation is reversed. Reverse typical atrial flutter has also been called clockwise atrial flutter, referring to the direction of endocardial activation from a left anterior oblique fluoroscopic perspective. The same anatomical and functional barriers described in typical atrial flutter are detected in reverse typical atrial flutter: double potentials are recorded at multiple levels in between the venae cavae, and the eustachian ridge^[64,65]. As in typical atrial flutter, complete transection of the inferior right atrial isthmus interrupts reverse typical atrial flutter, and prevents its recurrence^[66-68].

Reverse typical atrial flutter can be induced in the laboratory in about 50% of patients who clinically present with only typical (counterclockwise) atrial flutter. The 9:1 clinical predominance of typical (counterclockwise) atrial flutter may be related to the localization of an area with a low safety factor for conduction in the atrial flutter isthmus, close to the atrial septum^[69-71].

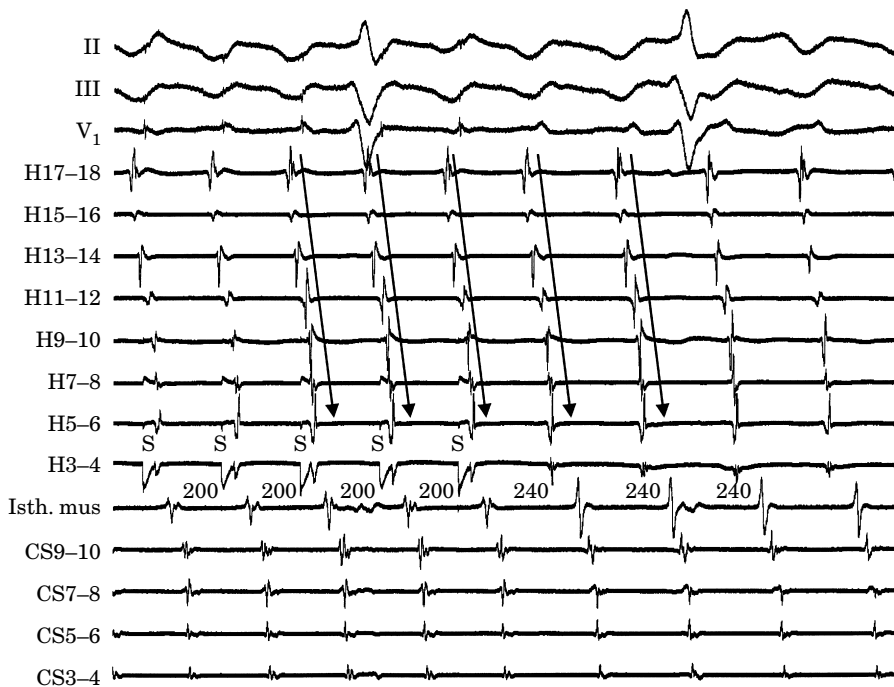


Figure 10 A return cycle identical to that of atrial tachycardia identifies a site within the reentrant circuit. End of a pacing run in typical atrial flutter. Recordings along the lateral wall are made by means of a duodecapolar 'halo' catheter from top (H17-18) to bottom i.e. the lateral side of the inferior vena cava–tricuspid annulus isthmus (H3-4). Pacing is initiated within the atrial flutter isthmus via the distal bipole of the halo catheter. Other recordings are the septal part of the isthmus via an ablation catheter and the coronary sinus (from proximal (CS9-10) to distal (CS3-4)). Note that all electrograms are accelerated at the rate of pacing whereas the surface ECG shows no discernable fusion. The first cycle following pacing cessation is identical to the atrial flutter cycle length, confirming isthmus dependence of the atrial tachycardia. During entrainment as well as during ongoing flutter, the activation is descending in the right atrial wall (arrows). This is a good example of concealed fusion.

ECG pattern

Reverse typical atrial flutter can be recognized with a high degree of reliability in the presence of broad, positive deflections in the inferior leads, although morphologies similar to that of typical atrial flutter have been reported. Wide negative deflections in V_1 may be the most specific diagnostic sign^[65,67] (Fig. 12). Reverse typical atrial flutter can produce other atypical patterns which need atrial mapping for precise diagnosis of the mechanism (Fig. 13)^[67].

Lesion macroreentrant atrial tachycardia

In this macroreentrant atrial tachycardia, the central obstacle of the circuit is an atriotomy scar, a septal prosthetic patch, a suture line, or a line of fixed block secondary to radiofrequency ablation^[7,72]. Other obstacles may also include anatomical structures located in the vicinity of the scar (superior vena cava/inferior vena cava). Low voltage electrograms characterizing areas of scar and flat bipolar recordings characterizing the prosthetic patch can be observed both during sinus

rhythm and during atrial tachycardia. Fixed block is present in the central obstacle and double potentials are recorded at linear scar lines (Fig. 7), similar to those recorded along lines of block in typical atrial flutter^[7,8].

Very complex and/or multiple reentry circuits can be seen after placement of an intra-atrial baffle (Mustard, Senning), in very dilated right atrium after a Fontan procedure, after Maze surgery^[73-75], and after endocardial radiofrequency ablation line for atrial fibrillation^[76]. After placement of an intra-atrial baffle to treat transposition of the great vessels, it may be impossible to map the entire circuit, due to the complex suture lines and baffles. Entrainment becomes an essential tool in these cases to confirm participation of specific areas in the circuit and to try to locate a suitable isthmus area from which concealed entrainment^[72] can be demonstrated. However, fusion can be, and usually is, very difficult to analyse in the ECG because of atypical, low voltage atrial complexes in the ECG, and concealed entrainment can be difficult to assess. Multiple endocardial recordings can help by showing local activation change (surrogate of fusion) during entrainment^[20].

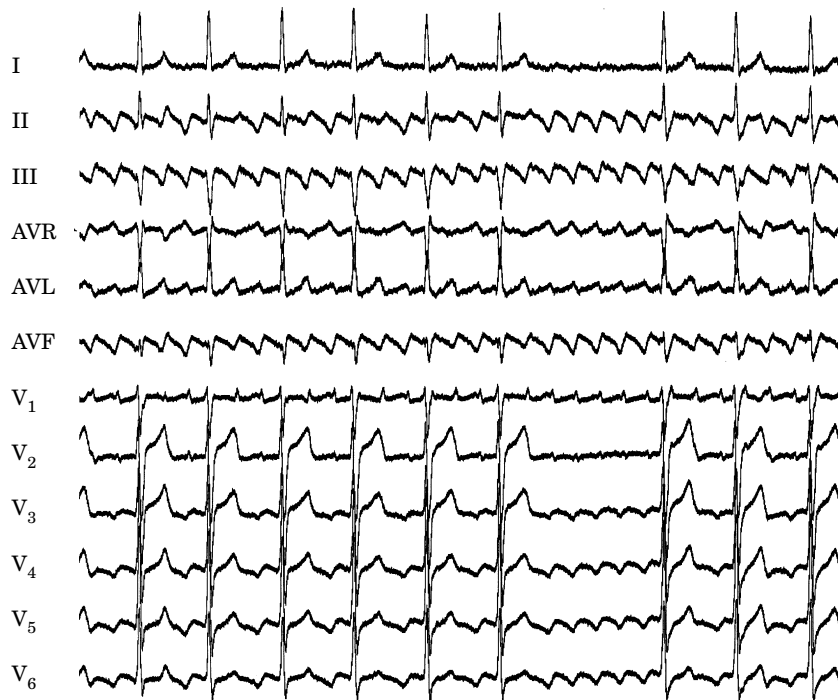

Figure 11 Twelve lead ECG of typical atrial flutter. The negative phase of the atrial flutter wave is well seen in the inferior leads. It is often followed by a positive notch that is synchronous with the positivity in V₁ and then by a slightly descending plateau.

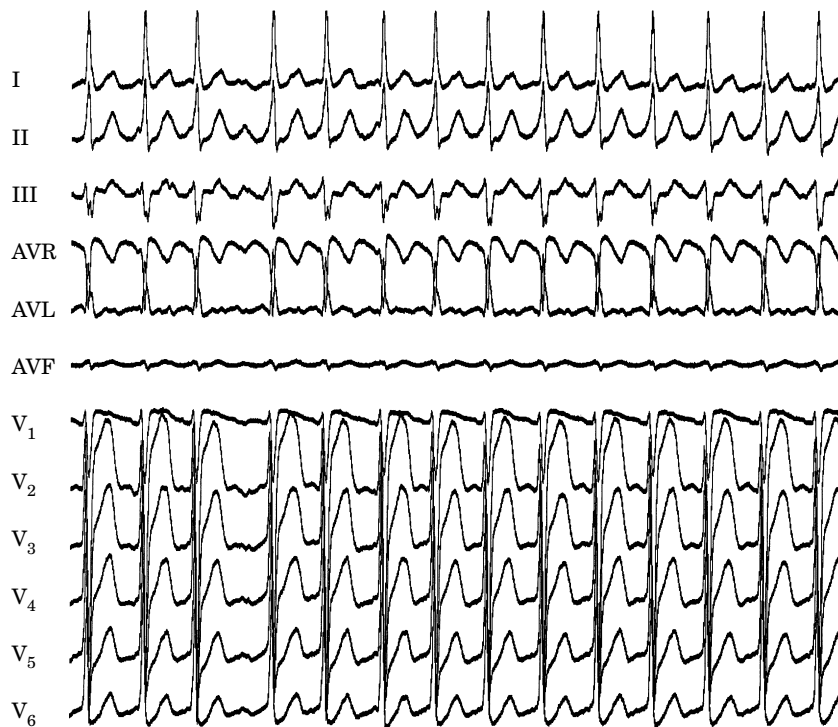


Figure 12 Twelve lead ECG of reversed typical atrial flutter. Agreement is weak regarding the ECG features of reverse right atrial rotation in typical atrial flutter. In the majority of the cases, the atrial flutter waves are described as predominantly positive in the inferior leads and negative in lead V₁.

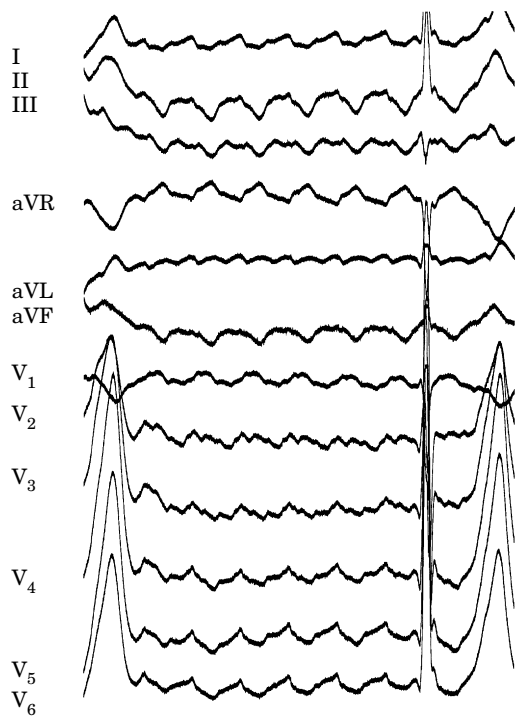


Figure 13 ECG in reverse typical atrial flutter. In selected cases, the ECG diagnosis of right atrial rotation of typical atrial flutter may be more difficult because of uncommon ECG patterns. In this case large notches are superimposed on the atrial flutter waves, which exhibit a more balanced undulating pattern, but are still predominantly negative in V_1 .

Right atrial free (lateral) wall atriotomy tachycardia

The best characterization of atriotomy macroreentrant atrial tachycardia is due to activation around an incision scar in the lateral right atrial wall, with a main supero-inferior axis^[7]. This deserves a separate description because it is the simplest model, is relatively common and relatively easy to study and ablate.

The anterior right atrial wall is commonly activated supero-inferiorly (descending), as in typical atrial flutter. However, the septal wall frequently lacks a clear cut infero-superior (ascending) activation pattern. Participation of the anterior right atrial wall in the circuit can be confirmed when the post-pacing cycle length is equal to the baseline cycle length. The return cycle length from the septum and flutter isthmus will be longer than the baseline cycle length. A line of double potentials is recorded in the lateral right atrium, extending supero-inferiorly. Double potential separation can be more marked, and demonstrate a voltage lower than in typical atrial flutter. Narrow passages (isthmuses) in the circuit can be found between the superior vena cava and the superior end of the atriotomy scar, the inferior vena cava and the inferior end of the atriotomy, the atriotomy scar and the tricuspid valve or the septal patch and the inferior vena cava or tricuspid valve or even within the scar itself^[49,72,77-80]. These isthmuses can be areas of slow conduction (Fig. 7). Stable pacing of the critical

isthmus can be difficult or impossible in right atrial atriotomy tachycardia because of atrial tachycardia interruption. Isthmus participation in the circuit is often proven by atrial tachycardia interruption with catheter pressure (Fig. 14), and atrial tachycardia interruption and non-inducibility after radiofrequency application in the area^[72,81]. A single, wide, fractionated electrogram can be recorded from the lower pivot point of the circuit in the low lateral right atrium, close to the inferior vena cava (Fig. 7), and perhaps also from other isthmuses of the circuit, closer to the tricuspid valve. The line of double potentials or fractionated, low voltage electrograms can also often be recorded in sinus rhythm allowing tentative localization of the scar and the associated anatomical isthmuses.

Typical atrial flutter is often associated with right atrial atriotomy tachycardia^[49]. Not uncommonly, ablation of one will unmask the other, and ablation of both circuits will be necessary for clinical success. Detection of this change requires careful attention to the atrial activation sequence and ECG pattern after each radiofrequency application. The recording of multiple simultaneous electrograms, as continuous endocardial references, will facilitate detection of these activation changes.

ECG patterns

The morphology of the atrial complex in the ECG of incisional macroreentrant atrial tachycardia can range from that which is similar to typical atrial flutter, to that which is characteristic of 'classical' atrial tachycardia (Fig. 15). In a patient with a previous atriotomy, any ECG pattern could be due to incisional macroreentrant atrial tachycardia. Often, more than one atrial tachycardia mechanism can be demonstrated and related to more than one ECG pattern.

Other macroreentrant tachycardias of the right atrium

Some unusual macroreentrant tachycardias appearing either after ablation or pacing in patients with typical flutter have been characterized. 'Lower loop reentry' has been the term proposed for counterclockwise reentry around the inferior vena cava where the anterior arm of the circuit is the inferior vena cava-TV isthmus and the posterior arm is the low posterior right atrial wall with conduction across the crista terminalis, making it a variant of typical atrial flutter in which the superior turn around is lower^[57]. In other cases, electro-anatomical or conventional mapping shows activation rotating around areas of low voltage electrograms in the right atrial free wall, not due to surgical scars, without inferior vena cava-TV isthmus participation^[82]. The ECG in both of these types of tachycardia tend to show negative atrial complexes in the inferior leads. Double wave reentry is another macroreentrant tachycardia in which two wavefronts circulate simultaneously in the same reentrant

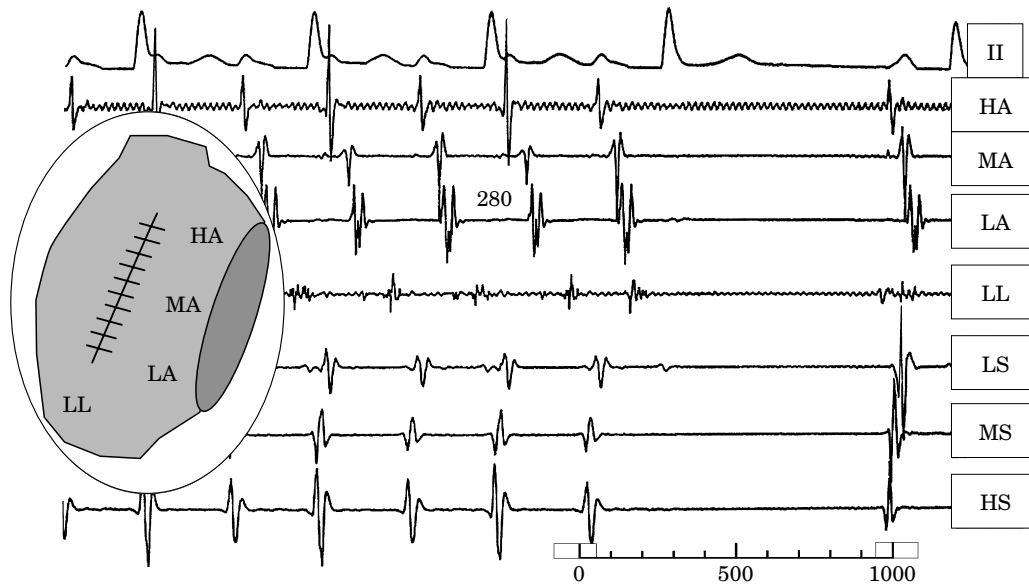


Figure 14 Interruption of incisional macroreentrant atrial tachycardia by catheter pressure over the critical isthmus. From top to bottom: lead II and recordings from the high anterior (HA), mid anterior (MA), low anterior (LA), low lateral (LL), low septal (LS), mid septal (MS) and high septal (HS) right atrium. The LL electrogram is obtained with the roving catheter. Positioning the catheter at this site reproducibly interrupted the macroreentrant tachycardia (probably by mechanically induced depolarization). Note that, although late, the local electrogram is slightly advanced at the time of tachycardia interruption without any discernable change in the timing of the other electrograms, further supporting the critical role of this area.

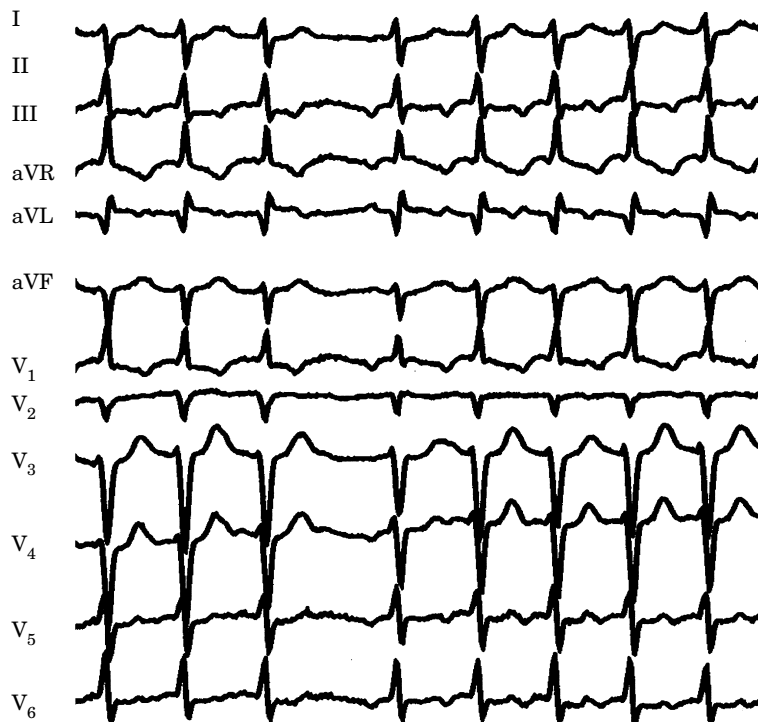


Figure 15 ECG pattern during an incisional macroreentrant atrial tachycardia. In this example, right atrial reentry with a cycle length of 490 ms occurs with the impulse rotating around the atriotomy scar.

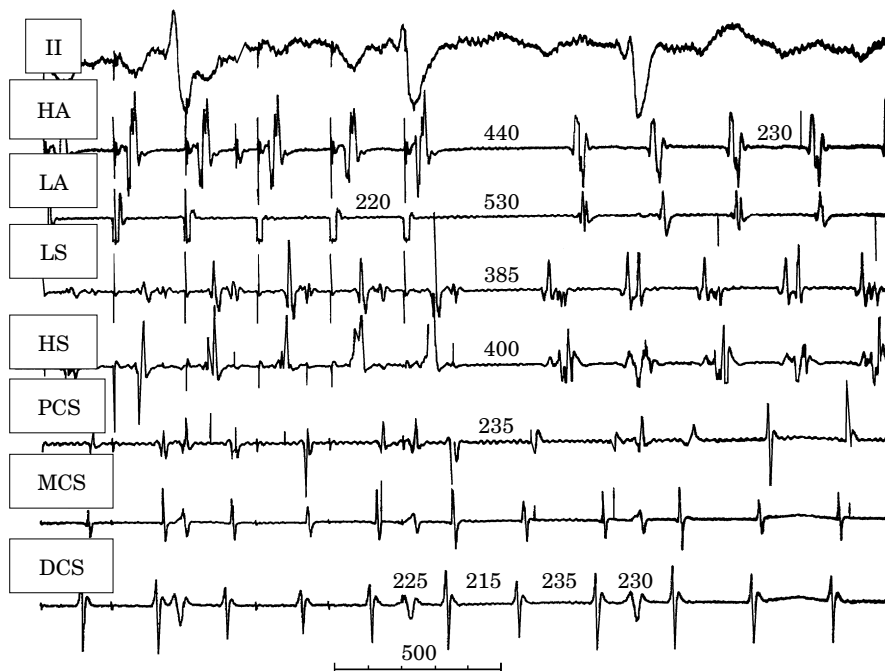


Figure 16 Left atrial macroreentrant atrial tachycardia with a reentrant right atrial activation pattern. Entrainment of left atrial macroreentrant tachycardia with ‘circular’ counterclockwise right atrial activation after isthmus ablation for typical atrial flutter. From top to bottom, recordings are lead II and electrograms from high anterior (HA), low anterior (LA), low septal (LS) and high septal (HS) right atrium, and proximal (PCS), mid (MCS) and distal (DCS) coronary sinus. On the right, after pacing, the baseline ECG and activation sequence are shown. Note an atrial flutter pattern on lead II resembling typical atrial flutter. Anterior wall activation is descending and septal activation ascending, as in typical counterclockwise atrial flutter. On the left, the mid anterior right atrium is paced at a cycle length of 220 ms. Note the reversal of septal activation, advancement of PCS in relation to MCS, but no change in DCS–MCS sequence and morphology. This demonstrates a partial activation change (equivalent to fusion in the ECG) and collision of activation fronts in the coronary sinus. The return cycle length after pacing is long in all right recordings but equal to the baseline cycle length in the coronary sinus recordings.

circuit^[83]. To date, it has only been described as using the typical reentrant circuit. It is an unstable rhythm, and generally of brief duration.

Left atrial macroreentrant atrial tachycardia

A stable macroreentrant atrial tachycardia can originate in the left atrium. The clinical incidence is not well known but may be 1/10th that of typical atrial flutter. There is still little information on the anatomical bases of left atrial macroreentry tachycardia, although recent reports have characterized the substrate as showing wide scarred areas with low voltage or absent electrograms^[84]. Detailed mapping of these atrial tachycardias is difficult because of the need for transeptal catheterization. However, the diagnosis can be made with reasonable certainty with the help of right atrial, coronary sinus, oesophageal and right pulmonary artery recordings^[85–87].

In the absence of left atrial mapping through transeptal catheterization, long segments of cycle length may not be covered by recorded electrograms (Fig. 9). Left atrial recordings can be obtained from the coronary sinus, the oesophagus and the pulmonary arteries to help fill these gaps in activation.

Right atrial mapping typically shows non-reentrant activation patterns, clearly different from typical and reversed typical atrial flutter^[81]. Early right atrial septal activation relative to other parts of the right atrium could suggest a focal septal origin in some cases when left atrial recordings are not obtained. The activation sequence of the coronary sinus is typically from distal to proximal or from mid coronary sinus to both proximal and distal coronary sinus. Cycle length variation in the right atrium, largely exceeding those of the left atrium, suggest a left atrial origin of the tachycardia^[84].

Local right atrial conduction disturbances, such as inferior right atrial isthmus block and/or transverse block at the crista terminalis can result in activation of

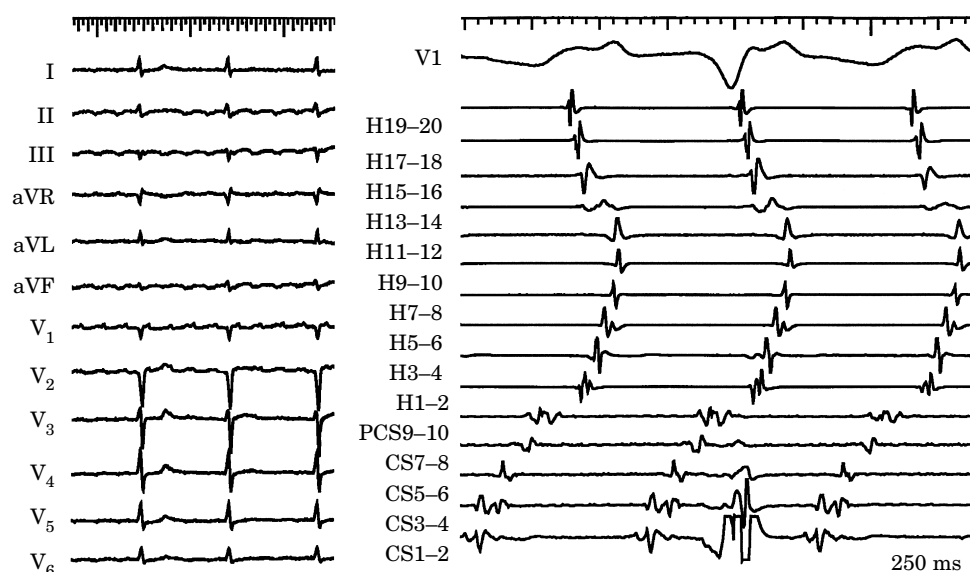


Figure 17 Atypical atrial flutter due to left atrial macroreentrant atrial tachycardia. Endocardial activation mapping shows that during atrial flutter, activation proceeds from the distal to the proximal coronary sinus, and then to the infero lateral wall of the right atrium. The higher portion of the lateral wall of the right atrium is depolarized in a descending fashion, presumably after activation via the Bachman bundle. The ECG shows a low voltage continuously undulating atypical atrial flutter. H19-20 to H1-2 represent recordings from a halo catheter in the right atrium in the usual position. CS1-2 to CS9-10 represent the recording of a decapolar catheter that is pushed in the coronary sinus, the distal coronary sinus being CS1-2.

the anterior and septal right atrium in opposite directions, mimicking reentrant right atrial activation of typical atrial flutter. In these cases the response to pacing (entrainment) will clarify location of the reentrant circuit (Fig. 15). A long local return cycle length after pacing the low anterior, low septal and low isthmus excludes participation of these areas in a reentry circuit. Return cycles will be close to the basic cycle length in the coronary sinus recordings. During entrainment of left atrial macroreentrant atrial tachycardia, it is usually possible to demonstrate partial change of activation or collision of activation fronts in the coronary sinus recordings, that become more marked with shorter pacing cycle length. Significant conduction delays can develop within left atrial macroreentrant circuits at high pacing rates, making the return cycle length progressively longer with shortening of the pacing cycle length. When only right atrial sites are studied, a return cycle length prolongation with a shortening of the entrainment cycle length may falsely suggest overdrive suppression of an automatic focus (Fig. 9). In some cases, several reentrant circuit loops may coexist^[84].

ECG patterns

Left atrial macroreentrant atrial tachycardias can result in ECG patterns of atrial tachycardia (discrete P waves and isoelectric baseline) (Figs 6 and 9), typical atrial flutter (Fig. 16) or atypical atrial flutter with usually a predominantly positive F wave morphology in lead V₁ (Fig. 17).

The limits of classification

Atypical atrial flutter/tachycardia

With reference to our proposal of typicality, the term atypical atrial flutter should be defined as any tachycardia fulfilling the classical ECG definition of a continuously undulating pattern but not fitting the typical and reverse typical flutter patterns described above^[65,88]. If the flutter/tachycardia is stable enough to have its mechanism elucidated by mapping and entrainment studies, description of the mechanism should be used with or without the term atypical. It should be noted that, as mentioned above, macroreentry in the right atrial circuit responsible for atrial flutter can produce atypical ECG patterns.

However, atypical atrial flutters are often difficult to characterize because rhythm instability may lead to spontaneous or pacing-induced termination, making entrainment impossible^[65]. Because circuits may vary in size and locations^[89,90], new mapping techniques capable of simultaneous acquisition of multiple electrograms should be useful to characterize and ablate these tachycardias^[56,91,92].

Type I and type II atrial flutter

Due to the wide acceptance of the original classification of atrial flutter as types I and II by Wells *et al.*^[45], and

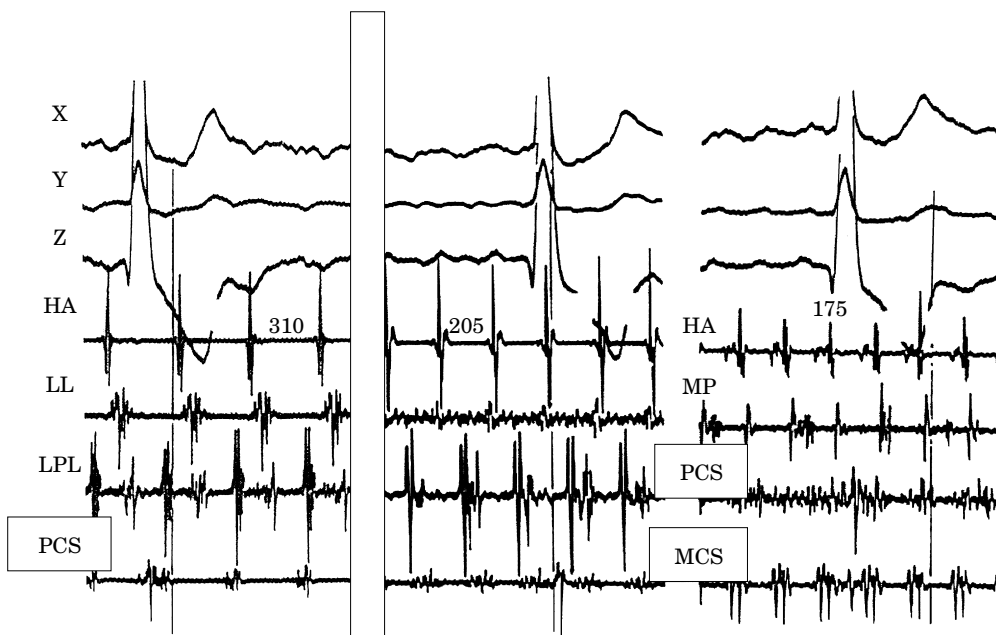


Figure 18 Type II atrial flutter. Rapid atrial flutter (type II?) induced by stimulation of typical atrial flutter. Orthogonal leads X, Y and Z and intracardiac electrograms are shown. HA=high anterior right atrium; LL=low lateral right atrium; LPL=low posterolateral right atrium; MP=mid posterior right atrium; MCS=mid coronary sinus; PCS=proximal coronary sinus. Baseline atrial flutter cycle length of 310 ms (left panel) shows a double electrogram over the low posterolateral wall. After rapid pacing the cycle length changes to 205 ms (centre panel), the double electrogram in LPL becomes narrowly split, there is continuous fractionated activity in the low lateral right atrium and a wide fractionated electrogram in PCS. Note atrial flutter pattern in lead X. After rapid pacing this second atrial flutter accelerates to cycle length 175 (right panel). An atrial flutter pattern is still present in X. Continuous fractionated activity is now recorded in PCS.

the widespread use of the term 'Type I atrial flutter' in the literature to designate typical atrial flutter, it is pertinent to refer to it briefly. Most macroreentrant atrial tachycardias and atrial flutters match the description of type I atrial flutter because this classification refers to baseline rate, stable intracardiac electrogram rate and morphology, and to the possibility of transient entrainment.

Type II atrial flutter was defined on the basis of a rapid rate ($>350 \text{ beats} \cdot \text{min}^{-1}$) and the inability to be entrained. However, there are no further systematic electrophysiological studies of type II atrial flutter, and the mechanism is unknown. In the electrophysiological laboratory and in the postoperative period, it is not unusual to induce a rapid (cycle length $\leq 180 \text{ ms}$), atypical atrial flutter/tachycardia while trying to interrupt typical atrial flutter by pacing^[45]. These atrial tachycardias are often unstable, returning spontaneously to typical atrial flutter, or degenerating into atrial fibrillation. Such tachycardias cannot be entrained, thus fitting the description of type II atrial flutter. Even if entrainment is not demonstrated, activation patterns can be changed by pacing at a very short cycle length, suggesting modification of the mechanism. This tachycardia can show continuous activity and/or fractionated electrograms in selected recording sites in either

atrium^[93,94] (Fig. 18). This atrial tachycardia is compatible with reentrant mechanisms, such as described by Allesie *et al.* in a Langendorff preparation in the dog, during acetylcholine infusion^[89]. It is possible that this type of tachycardia, fitting the description of type II atrial flutter is only a laboratory artifact, secondary to aggressive pacing. However, recent studies have suggested that type II atrial flutter may drive the atria at short cycle lengths producing fibrillatory conduction and, thereby, an ECG pattern of atrial fibrillation^[94].

Fibrillatory conduction

Multiple endocardial recordings in irregular atrial tachycardias may show relatively organized, regular activation sequences localized to some areas, simultaneous with irregular, changing activation patterns and electrogram fragmentation in others^[95] (Fig. 19). The ECG may show irregular activity, suggestive of atrial fibrillation. Only detailed, simultaneous multisite recordings from both atria can show these patterns. This pattern is compatible with local reentry or focal activity, associated with irregular intra-atrial conduction resulting in irregular activation patterns at a distance^[96]. Recent animal work suggests that stable local reentry (rotors)

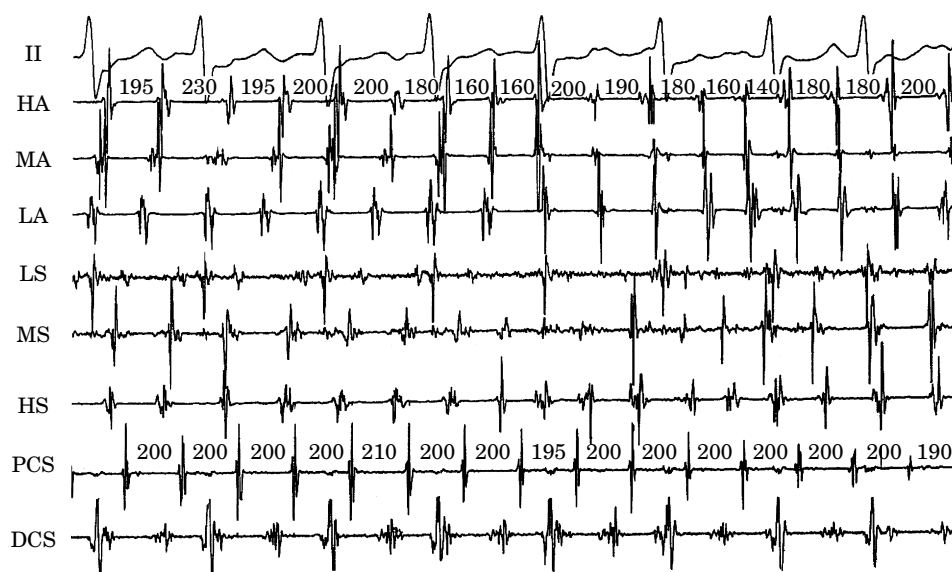


Figure 19 Fibrillatory conduction. Regular left atrial tachycardia with fibrillatory conduction to the right atrium. From top bottom, ECG lead II and recordings from the high anterior (HA), low anterior (LA), high septal (HS), mid septal (MS) and low septal (LS) right atrial and proximal (PCS) and distal (DCS) coronary sinus. Note the regular cycle length and activation sequence at proximal (PCS) and distal coronary sinus (DCS) and the changing cycle length and activation sequences in the anterior and septal right atrial recordings. This could be explained by irregular ('fibrillatory') conduction to the right atrium of rapid rate activation generated in the left atrium.

may be a mechanism of stabilization of atrial fibrillation, but there is currently not enough information to know the actual prevalence of these mechanisms in man^[97]. A parent arrhythmia is beyond the scope of a classification of atrial flutter and tachycardia as it deals with atrial fibrillation. This is the so-called focal atrial fibrillation during which very high rates bursts of atrial premature complexes, mainly non-sustained and coming from the pulmonary veins, are followed by complete atrial desynchronization that persist after the extinction of the triggering event^[98].

Reentrant sinus tachycardia

Early studies of sinus node function described the response to programmed single extrastimuli. The curve produced by plotting return cycles against the coupling interval could be divided into several phases, including compensatory pause, reset, interpolation and re-entry^[99,100]. Sinus node reentrant tachycardia was described on the basis of these findings as a tachycardia that could be induced and terminated by programmed stimulation with P wave morphology identical or similar to spontaneous P waves and cycle lengths of 350–550 ms^[101–103]. There are some reports of endocardial ablation of reentrant sinus tachycardia identified by these criteria^[104,105].

However, the precise identification of reentrant sinus tachycardia remains elusive. As indicated above, the mechanism of focal tachycardia can be reentrant, the

cycle length completely overlaps that described for sinus node reentrant tachycardia and the location of tachycardia foci is often over the crista terminalis, very close to the supposed location of the sinus node. An added problem is that the origin of the sinus activation can be quite variable according to epicardial mapping studies^[106]. Furthermore, endocardial origin of sinus activation during sinus rhythm has not been systematically studied in man, and specific criteria do not exist to pinpoint a specific sinus node area. Finally, reentry strictly limited to the sinus node area has never been demonstrated, and has even been questioned^[107].

Inappropriate sinus tachycardia

Inappropriate sinus tachycardia is a form of focal tachycardia originating in the sinus node at rates above the physiological range, but without an appropriate relationship to metabolic or physiological demands^[108,109]. In general, the site of origin of activation changes and moves down along the crista terminalis as a function of changes in autonomic tone, whereas in focal tachycardia it remains fixed. The borderline between inappropriate sinus tachycardia and focal atrial tachycardia originating in the crista terminalis is relatively imprecise. The term postural orthostatic tachycardia syndrome is a form of dysautonomia which is not anatomically based, but can be identified during head upright tilt table testing and improved by fludrocortisone^[110].

Summary: proposal for a classification

Atrial tachycardias are regular atrial rhythms at a constant rate ≥ 100 beats \cdot min⁻¹ originating outside the sinus node region. The mechanism can be focal or macroreentrant.

Electrocardiographically, flutter refers classically to a pattern of regular tachycardia with rate ≥ 240 beats \cdot min⁻¹ (cycle length ≤ 250 ms) lacking an isoelectric baseline between deflections. Neither rate nor lack of isoelectric baseline are specific of any tachycardia mechanism.

Focal atrial tachycardia is characterized by origin of activation from a circumscribed area with centrifugal spread to both atria. It can be due to enhanced automaticity, triggered activity or microreentry (very small reentry circuits).

Inappropriate sinus tachycardia is a form of atrial tachycardia originating along the superior aspect of the crista terminalis (in the 'sinus node region') at rates above the physiological range, but with no relationship to metabolic or physiological demands.

Macroreentrant atrial tachycardia is an atrial tachycardia due to a reentry circuit of large size with fixed and/or functional barriers. These circuits can be entrained during atrial pacing. Well characterized macroreentrant atrial tachycardias include

Typical atrial flutter
Reverse typical atrial flutter
Lesion macroreentrant tachycardia
Lower loop flutter
Double wave reentry
Right atrial free wall macroreentry without atriotomy
Left atrial macroreentrant tachycardia

Atypical atrial flutter is only a descriptive term for an atrial tachycardia with an ECG pattern of continuous undulation of the atrial complex, different from typical or reverse typical flutter, at a rate ≥ 240 beats \cdot min⁻¹. If the mechanism can be elucidated, either through conventional mapping and entrainment, or with special multipoint mapping techniques, description of the mechanism should accompany the term atypical flutter, otherwise it should be stated that the mechanism is unknown.

References

- [1] Schamroth L. The disorders of cardiac rhythm. Oxford: Blackwell, 1971: 49.
- [2] Puech P. L'Activité électrique auriculaire normale et pathologique. Paris: Masson & Cie, 1956.
- [3] Puech P, Latour H, Grolleau R. Le flutter et ses limites. Arch Mal Coeur 1970; 63: 116-44.
- [4] Cosío FG, Arribas F, Palacios J, Tascón J, López-Gil M. Fragmented electrograms and continuous electrical activity in atrial flutter. Am J Cardiol 1986; 57: 1309-14.
- [5] Cosío FG, Arribas F, Barbero JM, Kallmeyer C, Goicolea A. Validation of double spike electrograms as markers of conduction delay or block in atrial flutter. Am J Cardiol 1988; 61: 775-80.
- [6] Olshansky B, Okumura K, Hess PG, Waldo AL. Demonstration of an area of slow conduction in human atrial flutter. J Am Coll Cardiol 1990; 15: 833-41.
- [7] Lesh MD, Van Hare GF, Epstein LM *et al.* Radiofrequency catheter ablation of atrial arrhythmias: results and mechanisms. Circulation 1994; 89: 1074-89.
- [8] Cosío FG, Arribas F, López-Gil M, Palacios J. Atrial flutter mapping and ablation. I. Atrial flutter mapping. PACE 1996; 19: 841-53.
- [9] Olgin JE, Kalman JM, Fitzpatrick AP, Lesh MD. Role of right atrial structures as barriers to conduction during human type I atrial flutter. Activation and entrainment mapping guided by intracardiac echocardiography. Circulation 1995; 92: 1839-48.
- [10] Nakagawa H, Lazzara R, Khashgir T, Beckman KJ, McClelland JH, Imai S. Role of the tricuspid annulus and the eustachian valve/ridge on atrial flutter: relevance to catheter ablation of the septal isthmus and a new technique for rapid identification of ablation success. Circulation 1996; 94: 407-24.
- [11] Franz MR. Method and theory of monophasic action potential recording. Prog Cardiovasc Dis 1991; 33: 347-68.
- [12] Gornick CC, Adler SW, Pederson B, Hauck J, Budd J, Schweizer J. Validation of a new non contact catheter system for electroanatomical mapping of the left ventricular endocardium. Circulation 1999; 99: 829-35.
- [13] Schilling RJ, Kadish AH, Peters NS, Goldberger J, Wyn Davies D. Endocardial mapping of atrial fibrillation in the human right atrium using a non contact catheter. Eur Heart J 2000; 21: 550-64.
- [14] Gepstein L, Hayam G, Bentaim SA. A novel method for non fluoroscopic catheter based electroanatomic mapping of the heart: in vitro and in vivo accuracy results. Circulation 1997; 95: 1611-22.
- [15] Shpun S, Gepstein L, Hayam G, Ben-Haim SA. Guidance of radiofrequency endocardial ablation with real-time three-dimensional magnetic navigation system. Circulation 1997; 96: 2016-21.
- [16] Waldo AL, McLean WAH, Karp RB, Kouchoukos NT, James TN. Entrainment and interruption of atrial flutter with atrial pacing. Studies in man following open heart surgery. Circulation 1977; 56: 737-45.
- [17] Saoudi N, Anselme F, Poty H, Cribier A, Castellanos A. Entrainment of supraventricular tachycardias: A review. PACE 1998; 21: 2105-25.
- [18] Waldo AL, Plumb VJ, Arciniegas JG *et al.* Transient entrainment and interruption of A-V bypass pathway type paroxysmal atrial tachycardia. A model for understanding and identifying reentrant arrhythmias in man. Circulation 1982; 67: 73-83.
- [19] Okumura K, Henthorn RW, Epstein AE, Plumb VJ, Waldo AL. Further observations on transient entrainment: importance of pacing site and properties of the components of the reentry circuit. Circulation 1985; 72: 1293-1307.
- [20] Henthorn RW, Okumura K, Olshansky B, Plumb VJ, Hess PG, Waldo AL. A fourth criterion for transient entrainment: the electrogram equivalent of progressive fusion. Circulation 1988; 77: 1003-12.
- [21] Chen S-A, Chiang C-E, Yang C-J *et al.* Sustained atrial tachycardia in adult patients. Electrophysiological characteristics, pharmacological response, possible mechanisms, and effects of radiofrequency ablation. Circulation 1994; 90: 1262-78.
- [22] Wu D, Amat-y-Leon F, Denes P, Dhingra H, Pietras RJ, Rosen KM. Demonstration of sustained sinus and atrial reentry as a mechanism of paroxysmal supraventricular tachycardia. Circulation 1975; 51: 234-43.
- [23] Fisher JD, Lehmann MH. Marked intra-atrial conduction delay with split atrial electrograms: substrate for reentrant supraventricular tachycardia. Am Heart J 1986; 111: 781-4.
- [24] Castellanos A, Fernandez P, Luceri RM, Myerburg RJ. Mechanisms of atrial tachycardia. In: Attuel P, Coumel P,

- Janse MJ, eds. *The Atrium in Health and Disease*. Mt Kisco, NY: Futura Publishing Co, 1989: 263–9.
- [25] Josephson M. Supraventricular tachycardia. In: Josephson M, ed. *Clinical Cardiac Electrophysiology*. Malvern, PA: Lea & Febiger, 1993: 256–65.
- [26] Gillette PC, Crawford FC, Zeiger VL. Mechanisms of atrial tachycardia. In: Zipes DP, Jalife J, eds. *Cardiac Electrophysiology: From Cell to Bedside*. Philadelphia, PA: Saunders Publishing Co, 1990: 559–63.
- [27] Aronson RS, Hairman RJ, Gough WB. Delayed afterdepolarization and pathologic states. In: Rosen MR, Janse MJ, Wit AL, eds. *Cardiac Electrophysiology: A Textbook*. Mt Kisco, NY: Futura Publishing Co, 1990: 303–32.
- [28] Rosen MR, Reder RF. Does triggered activity have a role in the genesis of cardiac arrhythmias? *Ann Intern Med* 1981; 94: 794–801.
- [29] Wu D, Kuo HC, Hung JS. Exercise-triggered paroxysmal ventricular tachycardia: a repetitive rhythmic activity possibly related to afterdepolarization. *Ann Intern Med* 1981; 95: 410–14.
- [30] Waldo AL, Wit AL. Mechanism of Cardiac Arrhythmias and Conduction Disturbances. In: Fuster V, Alexander RW, King S, O'Rourke RA, Roberts R, Wellens HJJ, eds. *Hurst's The Heart*, 10th edn. New York, NY: McGraw-Hill Companies, in press.
- [31] Gillette PC, Garson A. Electrophysiologic and pharmacologic characteristics of automatic ectopic atrial tachycardia. *Circulation* 1977; 56: 571–5.
- [32] Seals AA, Lawrie GM, Magro S *et al*. Surgical treatment of right atrial focal tachycardia in adults. *J Am Coll Cardiol* 1988; 11: 1111–17.
- [33] Poty H, Saoudi N, Haïssaguerre M, Daou A, Clémenty J, Letac B. Radiofrequency catheter ablation of atrial tachycardias. *Am Heart J* 1996; 131: 481–9.
- [34] Pappone C, Stabile G, de Simone A *et al*. Role of catheter-induced mechanical trauma in localization of target sites of radiofrequency ablation in automatic atrial tachycardia. *J Am Coll Cardiol* 1996; 27: 1090–7.
- [35] Walsh EP, Saul JP, Hulse JE *et al*. Transcatheter ablation of ectopic atrial tachycardia in young patients using radiofrequency current. *Circulation* 1992; 86: 1138–46.
- [36] Tang CW, Scheinman MM, Van Hare GF *et al*. Use of P wave configuration during atrial tachycardia to predict site of origin. *J Am Coll Cardiol* 1995; 26: 1315–24.
- [37] Kalman JM, Olgin JE, Karch MR, Hamdan M, Lee RJ, Lesh MD. 'Cristal tachycardias'. Origin of right atrial tachycardias from the crista terminalis identified by intracardiac echocardiography. *J Am Coll Cardiol* 1998; 31: 451–9.
- [38] McGuire MA, Johnson DC, Nunn GR, Yung T, Uther JB, Ross DL. Surgical therapy for atrial tachycardia in adults. *J Am Coll Cardiol* 1989; 14: 1777–82.
- [39] Garson A, Gillette PC, Moak JP, Perry JC, Ott DA, Cooley DA. Supraventricular tachycardia due to multiple atrial ectopic foci: a relatively common problem. *J Cardiovasc Electrophys* 1990; 1: 132–8.
- [40] Goldreyer BN, Gallagher JJ, Damato AN. The electrophysiologic demonstration of atrial ectopic tachycardia in man. *Am Heart J* 1973; 85: 205–15.
- [41] Scheinmann MM, Basu D, Hollengerg M. Electrophysiologic studies in patients with persistent atrial tachycardia. *Circulation* 1974; 50: 266–73.
- [42] Davis J, Scheinman MM, Ruder MA *et al*. Ablation of cardiac tissues by an electrode catheter technique for treatment of ectopic supraventricular tachycardia in adults. *Circulation* 1986; 74: 1044–53.
- [43] Wyndham CRC, Arnsdorf MF, Levitsky S *et al*. Successful surgical excision of focal paroxysmal atrial tachycardia. Observations in vivo and in vitro. *Circulation* 1980; 62: 1365–72.
- [44] Sippens-Groenewegen A, Peeters HA, Jessurun ER *et al*. Body surface mapping during pacing at multiple sites in the human atrium: P-wave morphology of ectopic right atrial activation. *Circulation* 1998; 97: 369–80.
- [45] Wells JL, McLean WAH, James TN, Waldo AL. Characterization of atrial flutter. Studies in man after open heart surgery using fixed atrial electrodes. *Circulation* 1979; 60: 665–73.
- [46] Saoudi N, Mouton Schleiffer D, Letac B. Direct catheter fulguration of atrial flutter. *Lancet* 1987; 2 (8558): 568–9.
- [47] Saumarez RC, Parker J, Camm J. Geometrically accurate activation mapping of the atrioventricular node region during surgery. *J Am Coll Cardiol* 1992; 19: 601–6.
- [48] Stevenson WG, Nademanee K, Weiss J *et al*. Programmed electrical stimulation at potential reentry circuits sites. Comparison of observations in humans with predictions from computer simulations. *Circulation* 1989; 80: 793–806.
- [49] Chan DP, Van Hare GF, Mackall JA, Carlson MD, Waldo AL. Importance of atrial flutter isthmus in postoperative intra-atrial reentrant tachycardia. *Circulation* 2000; 102: 1283–9.
- [50] Friedman PA, Luria D, Fenton AM *et al*. Global and right atrial mapping of human atrial flutter: The presence of posteral-medial (sinus venosa region) double block and double potentials. *Circulation* 2000; 101: 1568–77.
- [51] Schumacher B, Jung W, Schmidt H *et al*. Transverse conduction capabilities of the crista terminalis in patients with atrial flutter and atrial fibrillation. *J Am Coll Cardiol* 1999; 34: 363–73.
- [52] Tai C-T, Chen S-A, Chen Y-J *et al*. Conduction properties of the crista terminalis in patients with typical atrial flutter: basis for a line of block in the reentrant circuit. *J Cardiovasc Electrophysiol* 1998; 9: 811–19.
- [53] Kalman J, Olgin J, Saxon L, Fisher W, Lee R, Lesh MD. Activation and entrainment mapping defines the tricuspid annulus as the anterior barrier in typical atrial flutter. *Circulation* 1996; 94: 398–406.
- [54] Tsuchiya T, Okumura K, Tabuchi T, Iwasa A, Yasue H, Yamabe H. The upper turnover site in the reentry circuit of common atrial flutter. *Am J Cardiol* 1996; 78: 1439–42.
- [55] Arribas F, López Gil M, Núñez A, Cosío FG. The upper link of the common atrial flutter circuit. *PACE* 1997; 20: 2924–9.
- [56] Shah D, Jaïs P, Haïssaguerre M *et al*. Three-dimensional mapping of the common atrial flutter circuit in the right atrium. *Circulation* 1997; 96: 3904–12.
- [57] Cheng J, Cabeen WR, Scheinmann MM. Right atrial flutter due to lower loop reentry. Mechanism and anatomic substrate. *Circulation* 1999; 99: 1700–5.
- [58] Cosío FG, López-Gil M, Goicolea A, Arribas R, Barroso JL. Radiofrequency ablation of the inferior vena cava-tricuspid valve isthmus in common atrial flutter. *Am J Cardiol* 1993; 71: 705–9.
- [59] Poty H, Saoudi N, Abdel Aziz A. Radiofrequency ablation of type 1 atrial flutter: Prediction of late success by electrophysiological criteria. *Circulation* 1995; 92: 1389–92.
- [60] Cauchemez B, Haïssaguerre M, Fischer B, Thomas O, Clémenty J, Coumel P. Electrophysiological effects of catheter ablation of inferior vena cava-tricuspid annulus isthmus in common atrial flutter. *Circulation* 1996; 93: 284–94.
- [61] Feld GK, Fleck RP, Chen P-S *et al*. Radiofrequency catheter ablation for the treatment of human type 1 atrial flutter. Identification of a critical zone in the reentrant circuit by endocardial mapping techniques. *Circulation* 1992; 86: 1233–40.
- [62] Cosío FG, López Gil M, Arribas F, Palacios J, Goicolea A, Núñez A. The mechanisms of entrainment of human common flutter studied with multiple endocardial recordings. *Circulation* 1994; 89: 2117–26.
- [63] Arenal A, Almendral J, San Roman D, Delcan JL, Josephson ME. Frequency and implications of resetting and entrainment with right atrial stimulation in atrial flutter. *Am J Cardiol* 1992; 70: 1292–8.
- [64] Cosío FG, Goicolea A, López-Gil M, Arribas F, Barroso JL, Chicote R. Atrial endocardial mapping in the rare form of atrial flutter. *Am J Cardiol* 1991; 66: 715–20.
- [65] Kalman JM, Olgin JE, Saxon LA, Lee RJ, Scheinman MM, Lesh MD. Electrocardiographic and electrophysiologic characterization of atypical atrial flutter in man: use of

- activation and entrainment mapping and implications for catheter ablation. *J Cardiovasc Electrophysiol* 1996; 8: 121–44.
- [66] Kirkorian G, Moncada E, Chevalier P *et al.* Radiofrequency ablation of atrial flutter: efficacy of an anatomically guided approach. *Circulation* 1994; 90: 2804–14.
- [67] Saoudi N, Nair M, Abdelazziz A *et al.* Electrocardiographic patterns and results of radiofrequency catheter ablation of clockwise type I atrial flutter. *J Cardiovasc Electrophysiol* 1996; 7: 931–42.
- [68] Tai C-T, Chen S-A, Chiang C-E *et al.* Electrophysiologic characteristics and radiofrequency catheter ablation in patients with clockwise atrial flutter. *J Cardiovasc Electrophysiol* 1996; 8: 24–34.
- [69] Olgin JE, Kalman JM, Saxon L, Lee RJ. Mechanism of initiation of atrial flutter in humans: Site of unidirectional block and direction of rotation. *J Am Coll Cardiol* 1997; 29: 376–84.
- [70] Tai C-T, Chen S-A, Chiang C-E *et al.* Characterization of low right atrial isthmus as the slow conduction zone and pharmacological target in typical atrial flutter. *Circulation* 1997; 96: 2601–11.
- [71] Cosío FG, López Gil M, Arribas F, González HD. Mechanisms of induction of typical and reversed atrial flutter. *J Cardiovasc Electrophysiol* 1998; 9: 281–91.
- [72] Triedman JK, Saul JP, Weindling SN, Walsh EP. Radiofrequency ablation of intra-atrial reentrant tachycardia after surgical palliation of congenital heart disease. *Circulation* 1995; 91: 707–14.
- [73] Cronin CS, Nitta T, Mitsuno M *et al.* Characterization and surgical ablation of acute atrial flutter following the Mustard procedure. A canine model. *Circulation* 1993; 88 (Suppl 2): 461–71.
- [74] Van Hare GF, Lesh MD, Ross BA, Perry JC, Dorostkar PC. Mapping and radiofrequency ablation of intraatrial reentrant tachycardia after the Senning or Mustard procedure for transposition of the great arteries. *Am J Cardiol* 1996; 77: 985–91.
- [75] Deal BJ, Mavroudis C, Backer CL, Johnsrude CL, Rocchini AP. Impact of arrhythmia circuit cryoablation during Fontan conversion for refractory atrial tachycardia. *Am J Cardiol* 1999; 83: 563–9.
- [76] Haïssaguerre M, Jais P, Shah DC *et al.* Right and left atrial radiofrequency catheter therapy of paroxysmal atrial fibrillation. *J Cardiovasc Electrophysiol* 1996; 7: 1132–44.
- [77] Kalman JM, van Hare GF, Olgin J, Saxon LA, Stark SI, Lesh MD. Ablation of ‘incisional’ reentrant atrial tachycardia complicating surgery for congenital heart disease: use of entrainment to define a critical isthmus of conduction. *Circulation* 1996; 93: 502–12.
- [78] Baker BM, Lindsay BD, Bromberg BI, Frazier DW, Cain ME, Smith JM. Catheter ablation of clinical intraatrial reentrant tachycardias resulting from previous atrial surgery: localizing and transecting the critical isthmus. *J Am Coll Cardiol* 1996; 28: 411–17.
- [79] Cosío FG, Arribas F, López Gil M, González D. Atrial flutter mapping and ablation II. Radiofrequency ablation of atrial flutter circuits. *PACE* 1996; 19: 965–75.
- [80] Anselme F, Saoudi N, Redonnet M, Letac B. Atrio-atrial conduction after orthotopic heart transplantation. *J Am Coll Cardiol* 1994; 24: 185–9.
- [81] Saoudi N, Redonnet M, Anselme F, Poty H, Cribier A. Catheter ablation of atrioatrial conduction as a cure for atrial arrhythmia after orthotopic heart transplantation. *J Am Coll Cardiol* 1998; 32: 1048–55.
- [82] Kall JG, Rubenstein DS, Kopp DE *et al.* Atypical atrial flutter originating in the right atrial free wall. *Circulation* 2000; 101: 270–9.
- [83] Cheng J, Scheinmann MM. Acceleration of typical atrial flutter due to double wave reentry induced by programmed electrical stimulation. *Circulation* 1998; 97: 1589–96.
- [84] Jais P, Shah DC, Haïssaguerre M *et al.* Mapping and ablation of left atrial flutters. *Circulation* 2000; 101: 2928–34.
- [85] Ogawa S, Dreifus LS, Kitchen JG, Shenoy PN, Osmick MJ. Catheter recording of Bachmann’s bundle activation from the right pulmonary artery: a new technique for atrial mapping and the study of supraventricular tachycardia (separatas 13.5.0.1). *Am J Cardiol* 1978; 41: 1089–1096.
- [86] Breithardt G, Seipel L. Recording of left atrial potentials from pulmonary artery in man. *Br Heart J* 1980; 43: 689–94.
- [87] Prystowsky EN, Pritchett ELC, Gallagher JJ. Origin of the atrial electrogram recorded from the esophagus. *Circulation* 1980; 61: 1017–23.
- [88] Lesh MD, Kalman JM. To fumble flutter or tackle ‘tach’? Toward updated classifiers for atrial tachyarrhythmias. *J Cardiovasc Electrophysiol* 1996; 7: 460–6.
- [89] Allesie MA, Lammers WJEP, Bonke FIM, Hollen J. Intra-atrial reentry as a mechanism for atrial flutter induced by acetylcholine and rapid pacing in the dog. *Circulation* 1984; 70: 123–35.
- [90] Kumagai K, Khrestian C, Waldo AL. Simultaneous multisite mapping studies during induced atrial fibrillation in the sterile pericarditis model. Insights into the mechanism of its maintenance. *Circulation* 1997; 95: 511–21.
- [91] Schilling RJ, Peters NS, Davies DW. Simultaneous endocardial mapping in the human left ventricle using a non contact catheter. Comparison of contact and reconstructed electrograms during sinus rhythm. *Circulation* 1998; 98: 887–98.
- [92] Gormick CC, Adler SW, Pederson B, Hauck J, Budd J, Schweitzer J. Validation of a new non contact catheter system for electroanatomic mapping of the left ventricular endocardium. *Circulation* 1999; 99: 829–35.
- [93] Cosío FG, Arribas F. Role of conduction disturbances in atrial arrhythmias. In: Attuel P, Coumel P, Janse MJ, eds. *The Atrium in Health and Disease*. New York: Futura, 1989: 133–58.
- [94] Waldo AL, Cooper TB. Spontaneous onset of Type I atrial flutter in patients. *J Am Coll Cardiol* 1996; 28: 707–12.
- [95] Cosío FG, Arribas F, López Gil M. Atrial fibrillation findings. In: Falk RH, Podrid PJ, eds. *Atrial Fibrillation. Mechanisms and Management*. Philadelphia: Lippincott-Raven, 1997: 397–410.
- [96] Schuessler RB, Grayson TM, Bromberg BI, Cox JL, Boineau JP. Cholinergically mediated tachyarrhythmias induced by a single extrastimulus in the isolated canine right atrium. *Circ Res* 1992; 71: 1254–67.
- [97] Mandapati R, Skanes A, Chen J, Berenfeld O, Jalife J. Stable microreentrant sources as a mechanism of atrial fibrillation in the isolated sheep heart. *Circulation* 2000; 101: 194–9.
- [98] Jais P, Haïssaguerre M, Shah DC *et al.* A focal source of atrial fibrillation treated by discrete radiofrequency ablation. *Circulation* 1997; 95: 572–6.
- [99] Dhingra RC, Wyndham C, Amat Y, Leon F *et al.* Sinus nodal responses to atrial extrastimuli in patients without apparent sinus node disease. *Am J Cardiol* 1975; 36: 445–52.
- [100] Strauss HC, Bigger JT, Saroff AL, Giardina EGV. Electrophysiology evaluation of sinus node function in patients with sinus node dysfunction. *Circulation* 1976; 53: 763–76.
- [101] Gomes JA, Hariman RJ, Kang PS, Chowdry IH. Sustained symptomatic sinus node reentrant tachycardia: Incidence, clinical significance, electrophysiologic observations and the effects of antiarrhythmic agents. *J Am Coll Cardiol* 1985; 5: 45–57.
- [102] Narula OS. Sinus node reentry: a mechanism for supraventricular tachycardia. *Circulation* 1974; 50: 1114–28.
- [103] Wu D, Amat Y, Leon F, Denes P, Dhingra RC, Pietrs RJ, Rosen KM. Demonstration of sustained sinus and atrial reentry as a mechanism of paroxysmal supraventricular tachycardia. *Circulation* 1975; 51: 234–43.
- [104] Saoudi N, Koning R, Eltchaninoff H, Cribier A, Letac B. L’ablation par radiofréquence dans le traitement des arythmies auriculaires. *Arch Mal Coeur* 1994; 87: 27–34.
- [105] Sanders WE, Sorrentino RA, Greenfield RA, Shenasa H, Hamer ME, Wharton JM. Catheter ablation of sino atrial

- node reentrant tachycardia. *J Am Coll Cardiol* 1994; 23: 926–34.
- [106] Boineau JP, Cnavan TE, Schuessler RB, Cain ME, Corr PB, Cox JL. Demonstration of a widely distributed atrial pacemaker complex in the human heart. *Circulation* 1987; 77: 1221–37.
- [107] Kirchhof CJHJ, Bonke FIM, Allessie MA. Sinus node reentry — Fact or fiction? In: Brugada P, Wellens HJJ, eds. *Cardiac arrhythmias. Where to go from Here?* Mt Kisco, NY: Futura Publishing Co, 1987: 53.
- [108] Morillo CA, Klein GJ, Thakur RK, Li H, Zardini M, Yee R. Mechanism of ‘inappropriate’ sinus tachycardia: role of sympathovagal balance. *Circulation* 1994; 90: 873–7.
- [109] Lee RJ, Kalman JM, Fitzpatrick AP *et al.* Radiofrequency catheter modification of the sinus node for ‘inappropriate’ sinus tachycardia. *Circulation* 1995; 92: 2918–28.
- [110] Karras B, Grubb BP, Boehm K, Kip K. The postural orthostatic tachycardia syndrome: A potentially treatable cause of chronic fatigue, exercise intolerance, and cognitive impairment in adolescents. *PACE* 2000; 23: 344–51.